

# TMJ/ORTHODONTICS CLINICAL CHART

## DOLPHIN 3D

- Transition from 2D to 3D Orthodontics
- 1) Segmentation
- 2) Orientation
- 3) Virtual 2D X-Rays development (lateral>orthopantomography>TMJ>cross sections>postero-anterior>upper arch submento-vertex>lower arch submento-vertex
- Cephalometrics > Transition to 3D cephalometrics
- 4) Virtual 2D
- 5) Virtual 3D muscles Dissections: Right Masseter>Left Masseter

## ~~INTRAORAL SCANNERS~~

File Edit View Options Tools Help

Volume:  Translucent  Solid

Soft Tissue

Seg:

Hard Tissue

Seg:

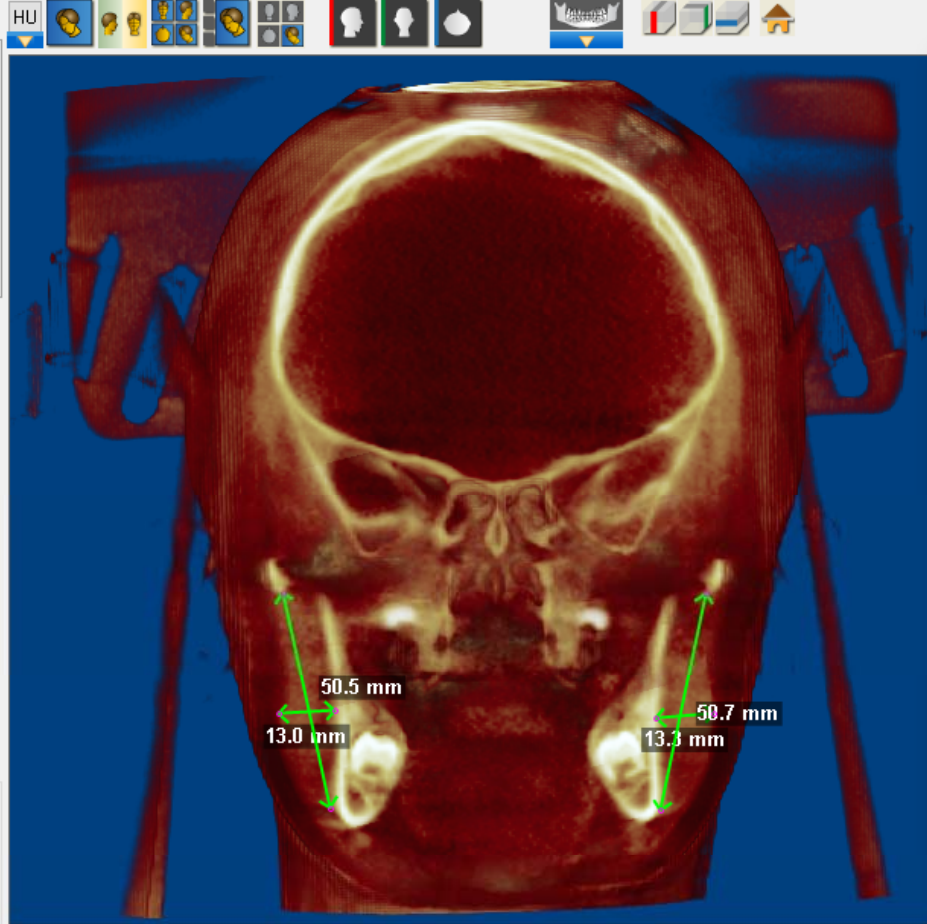
Opc:

Soft Tissue + Hard Tissue

Opc:

Photos/Surfaces:

Use Clipping Slice



Digitize/Measurement

View:

Analysis:

Landmark	3D Line	3D Angle	3D Path
2D Slice Area	2D Line	2D Angle	2D Path
Name	Value		
<input checked="" type="checkbox"/> 2D Line Distance 1 (Volume)	50.5		
<input checked="" type="checkbox"/> 2D Line Distance 2 (Volume)	50.7		
<input checked="" type="checkbox"/> 2D Line Distance 3 (Volume)	13.0		
<input checked="" type="checkbox"/> 2D Line Distance 4 (Volume)	13.3		
<input checked="" type="checkbox"/> <Add New - 2D Line Distance>	---		

\* Digitize 2 points to define line

Continue to show on images when this window closes

# TMJ/ORTHODONTICS CLINICAL CHART DOLPHIN 3D

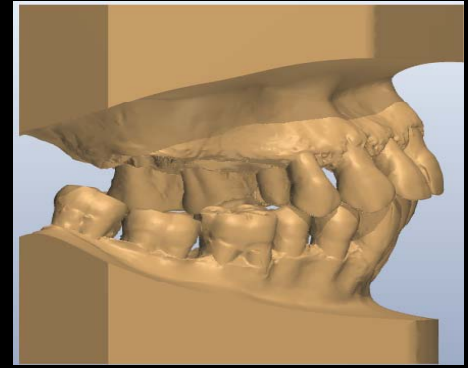
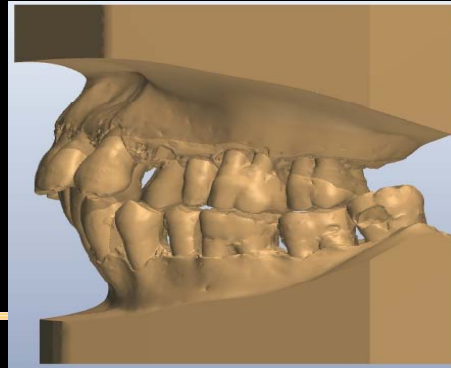
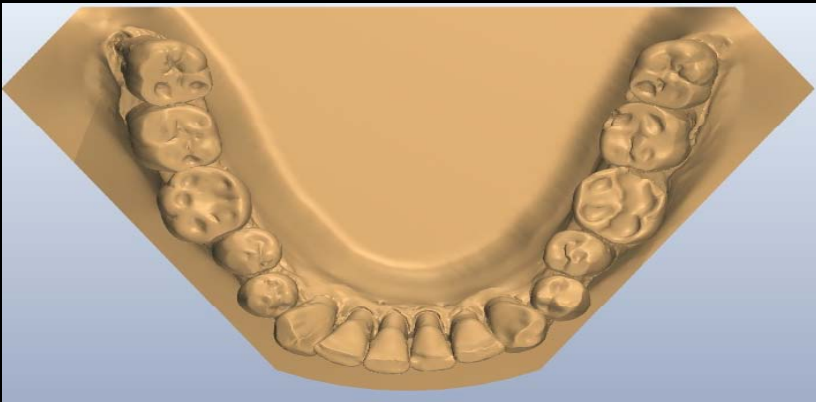
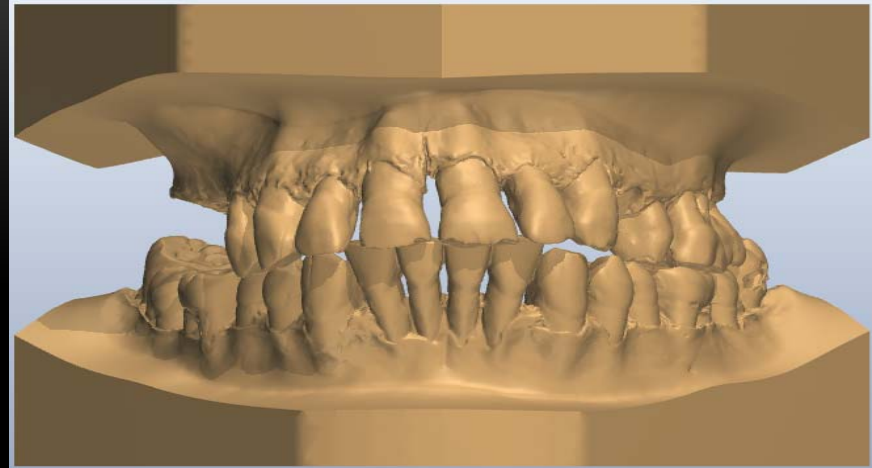
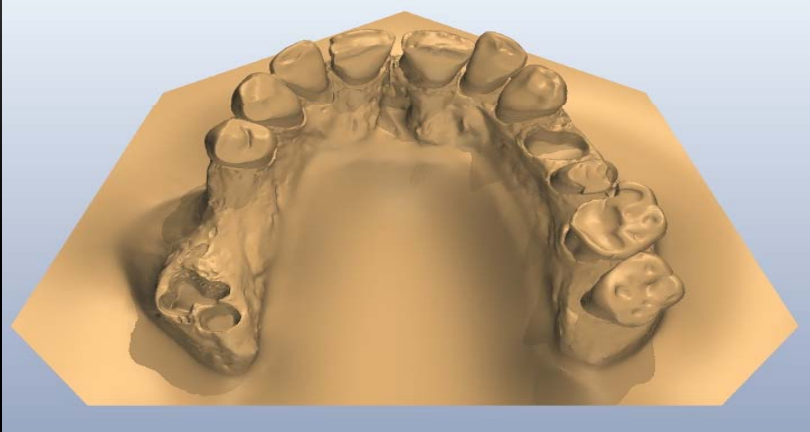
- Transition from 2D to 3D Orthodontics
- 1)Segmentation
- 2)Orientation
- 3)Virtual 2D X-Rays development (lateral>ortophantomography>TMJ>cross sections>postero-anterior>upper arch submento-vertex>lower arch submento-vertex
- Cephalometrics >Transitipon to 3D cehalometrics4)Virtual 2D
- 5) Virtual 3D muscles Dissections: Right Masseter>Left Masseter

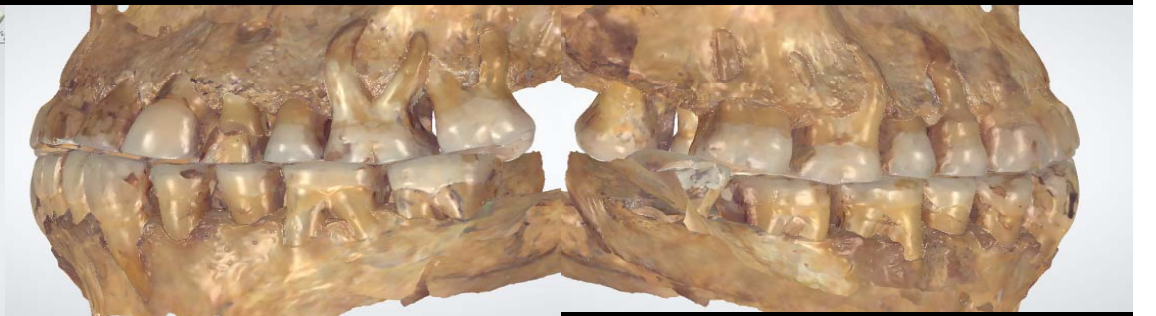
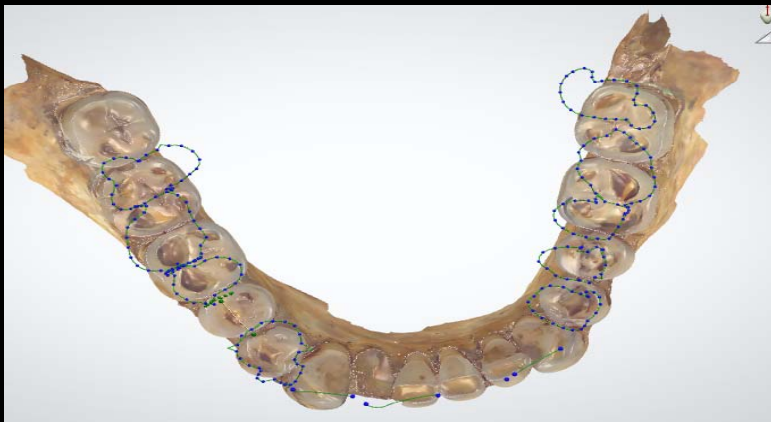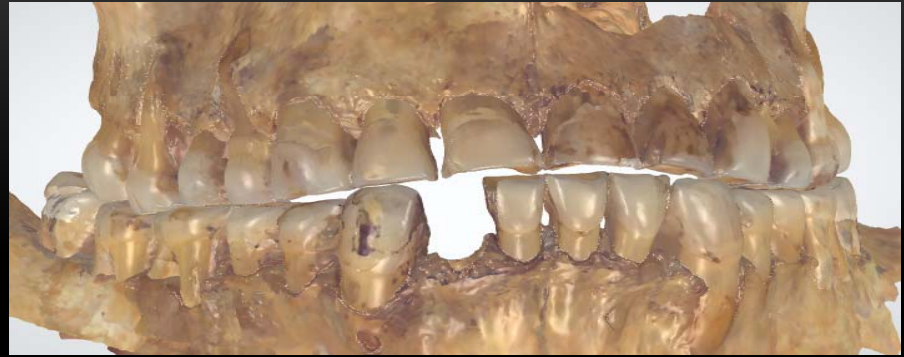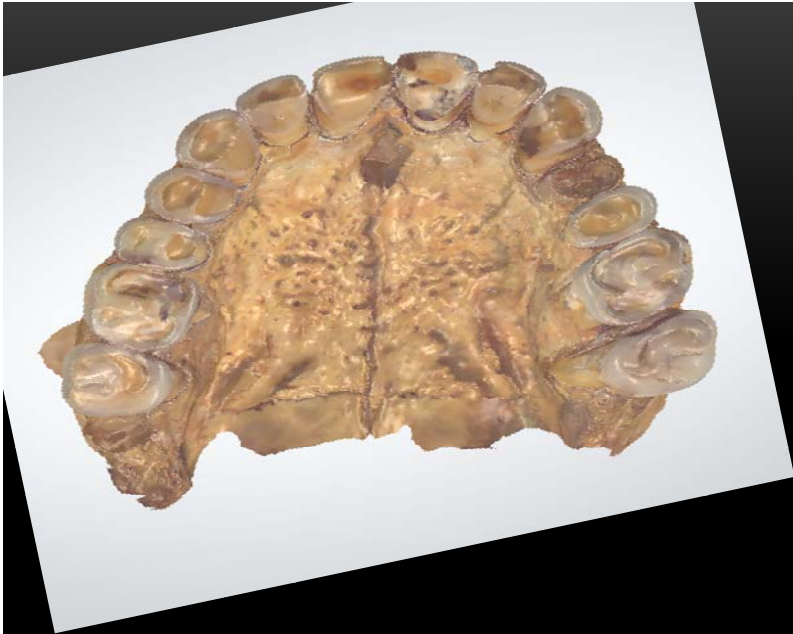
**INTRAORAL SCANNERS** Diagnosis Genomic  
3D Appliances

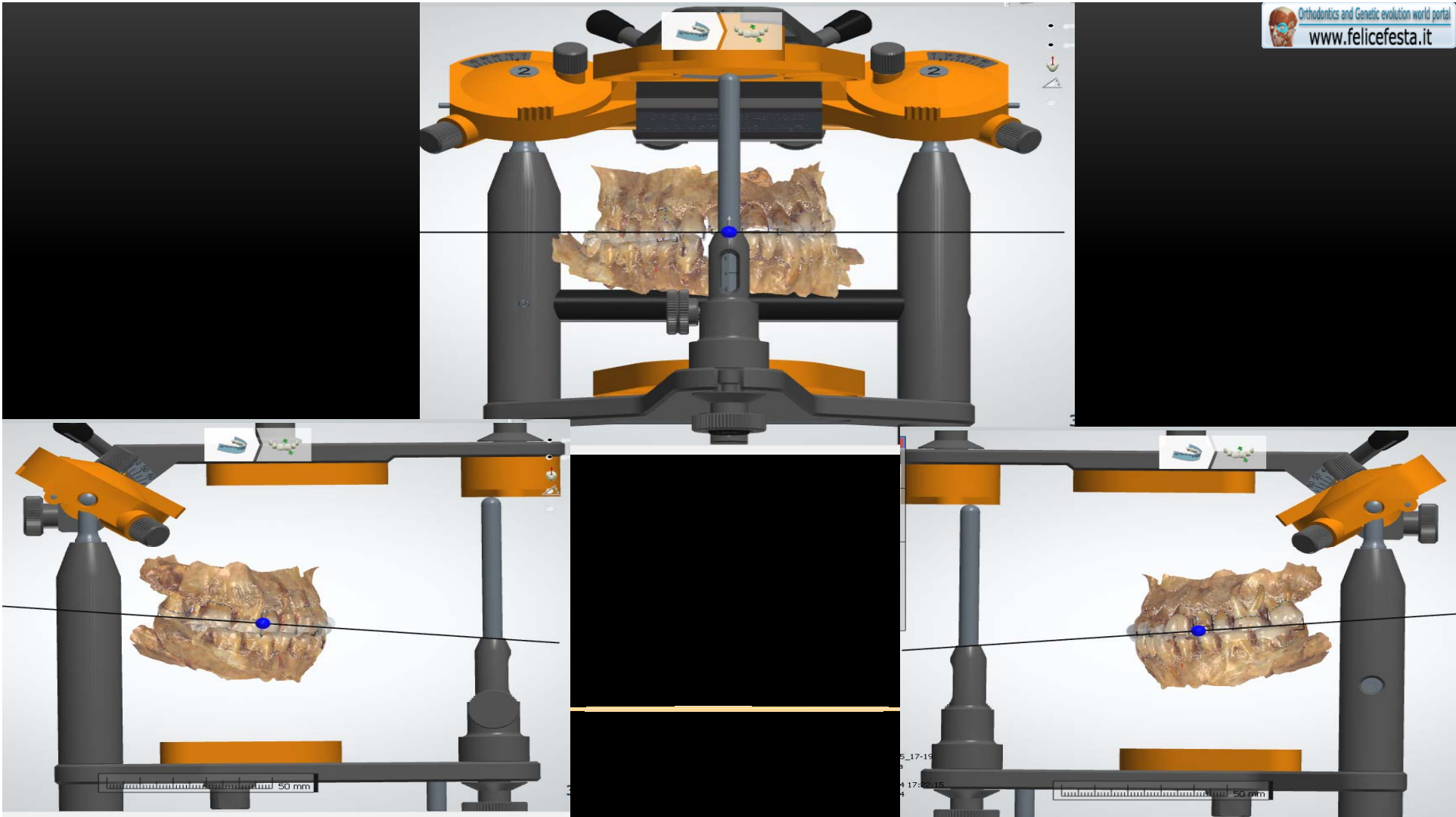
# TMJ/ORTHODONTICS CLINICAL CHART DOLPHIN 3D

- Transition from 2D to 3D Orthodontics
- 1)Segmentation
- 2)Orientation
- 3)Virtual 2D X-Rays development (lateral>ortophantomography>TMJ>cross sections>postero-anterior>upper arch submento-vertex>lower arch submento-vertex
- Cephalometrics >Transitipon to 3D cehalometrics4)Virtual 2D
- 5) Virtual 3D muscles Dissections: Right Masseter>Left Masseter

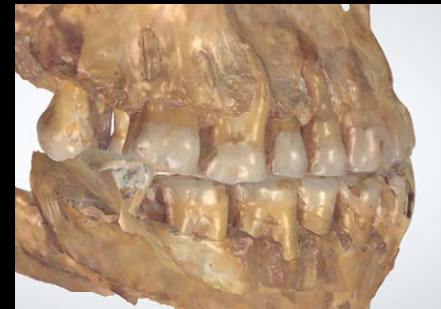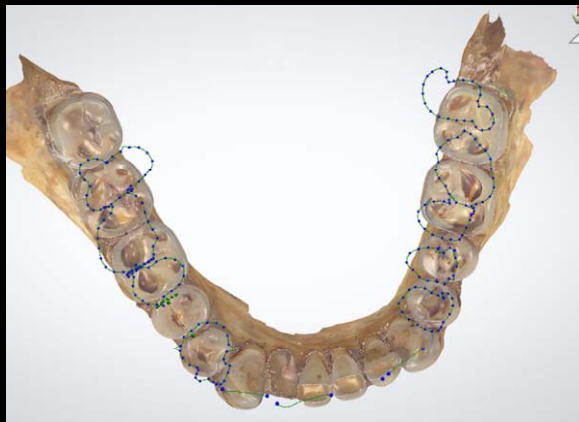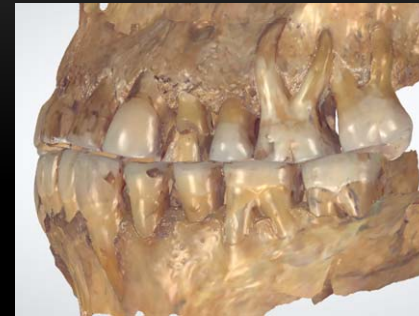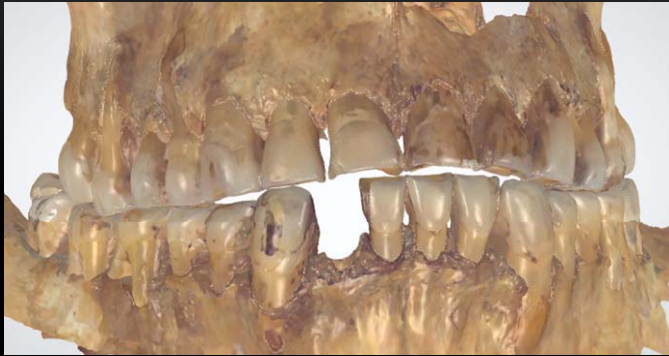**INTRAORAL SCANNERS** Diagnosis Genomic  
3D Appliances






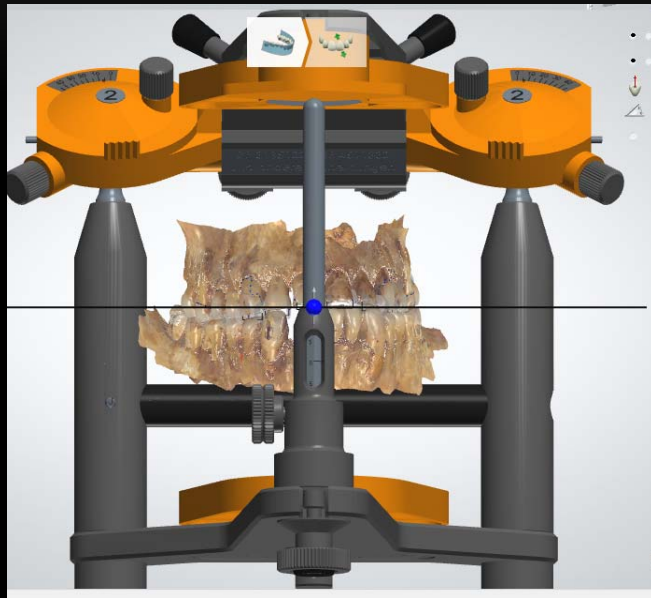


# 3D OPI ARCH RECONSTRUCTION





# 3D OPI ARCH VIRTUAL ARTICULATOR

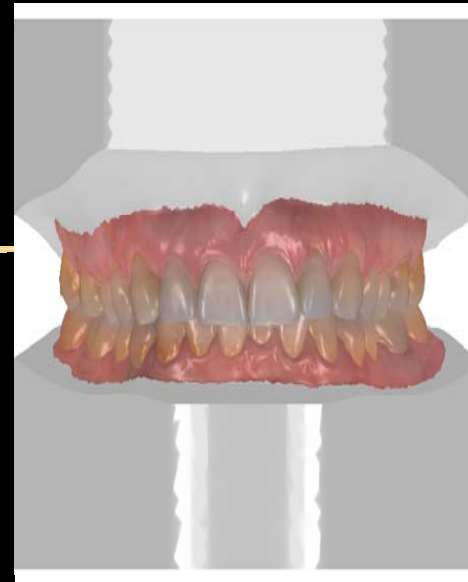
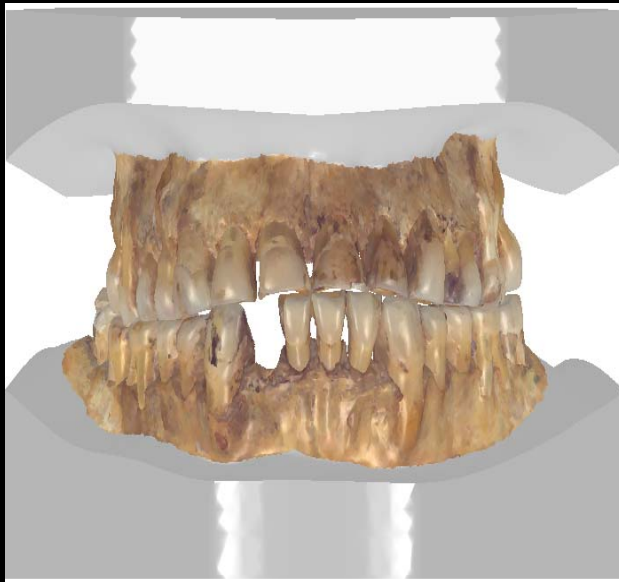

OPI ARCH

>

CONTEMPORARY ARCH

Front view

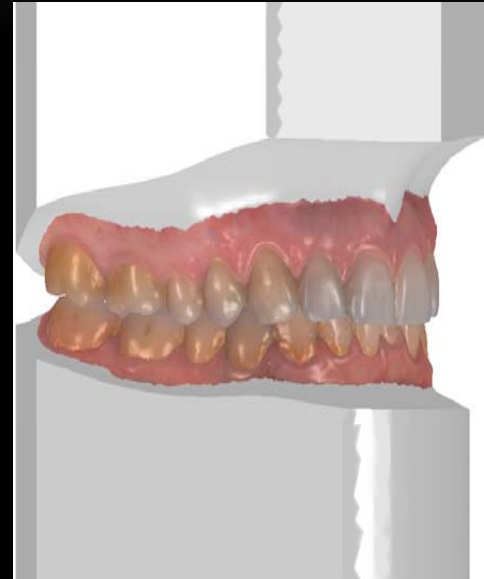
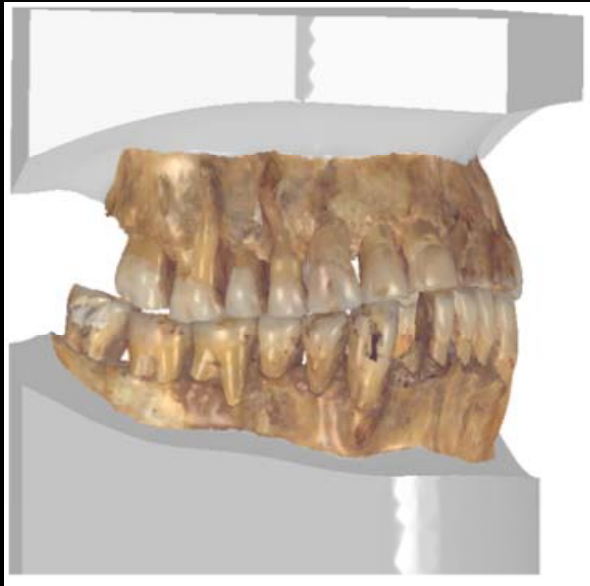
OPI ARCH

>

CONTEMPORARY ARCH

Right side

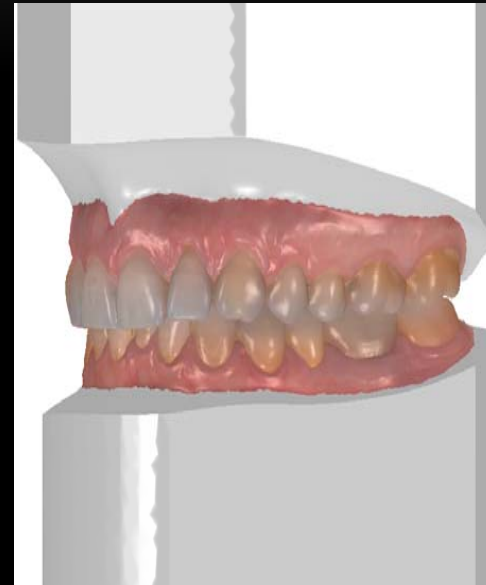
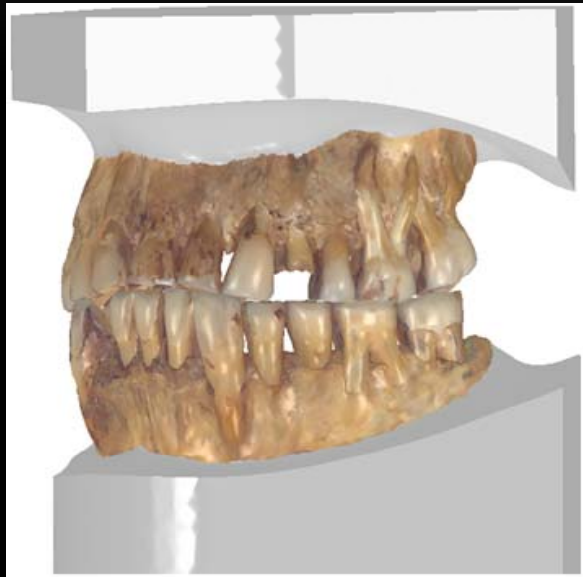
OPI ARCH

>

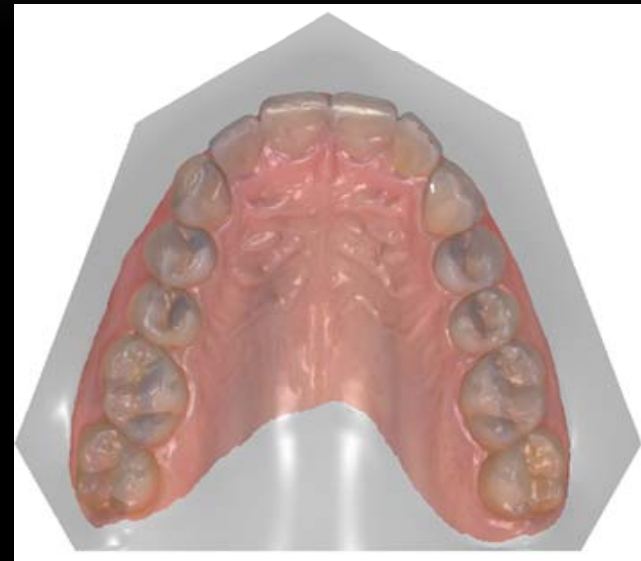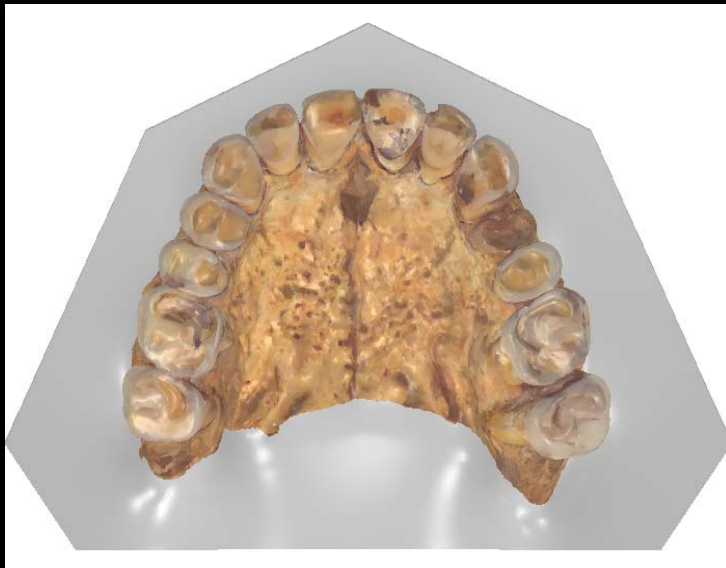
CONTEMPORARY ARCH

Left side



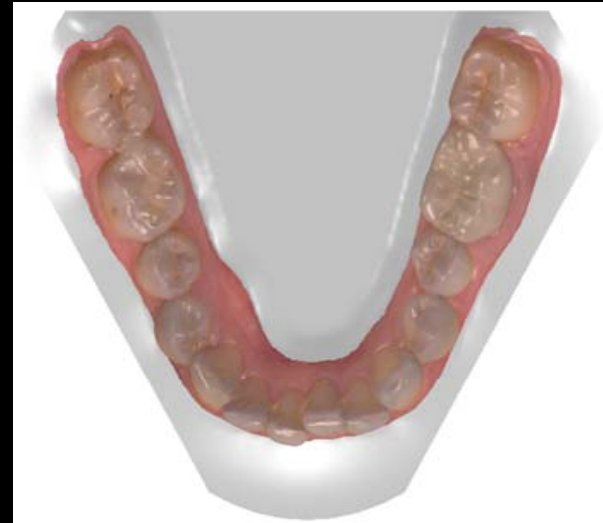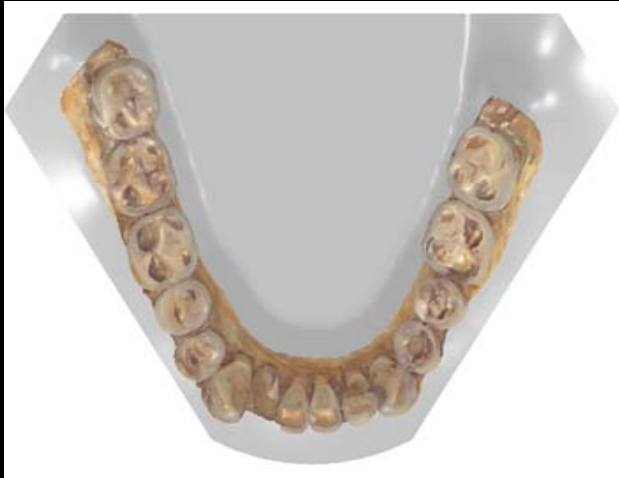# OPI ARCH > CONTEMPORARY ARCH

Maxillary occlusal view



# OPI ARCH > CONTEMPORARY ARCH

Mandibular occlusal view

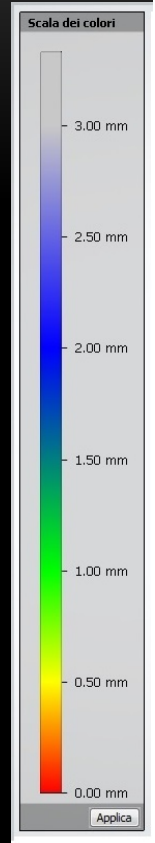
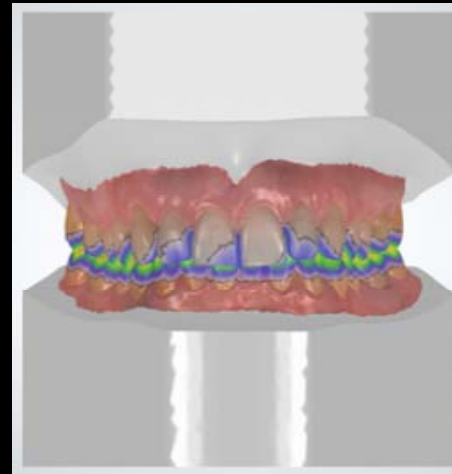
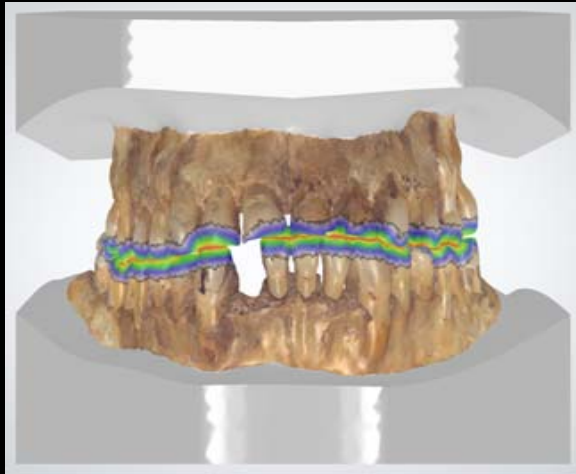


OPI ARCH

>

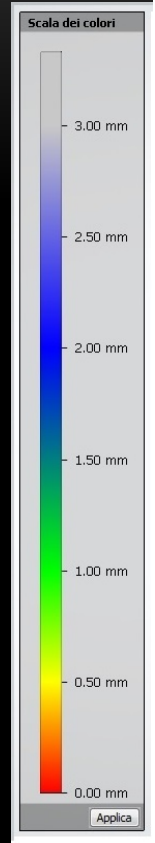
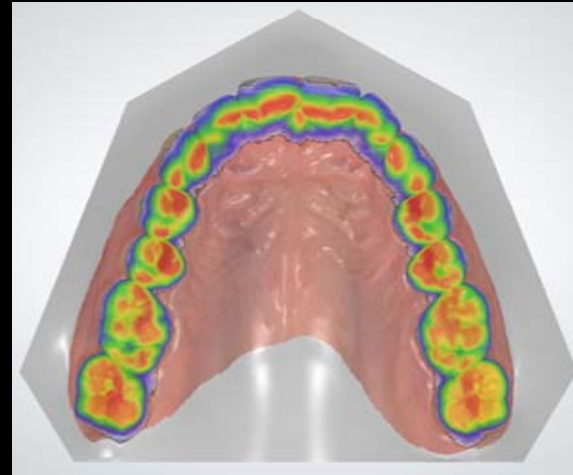
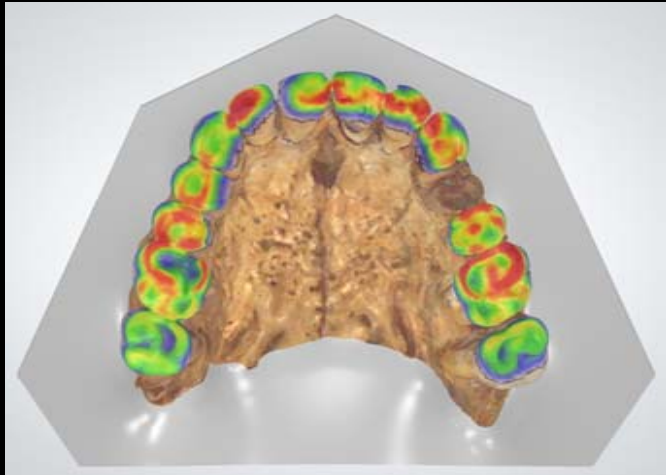
CONTEMPORARY ARCH

Occlusal contacts



# OPI ARCH > CONTEMPORARY ARCH

Maxillary contacts



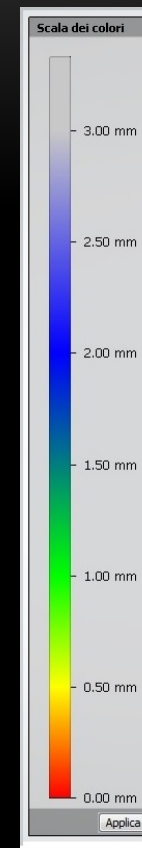
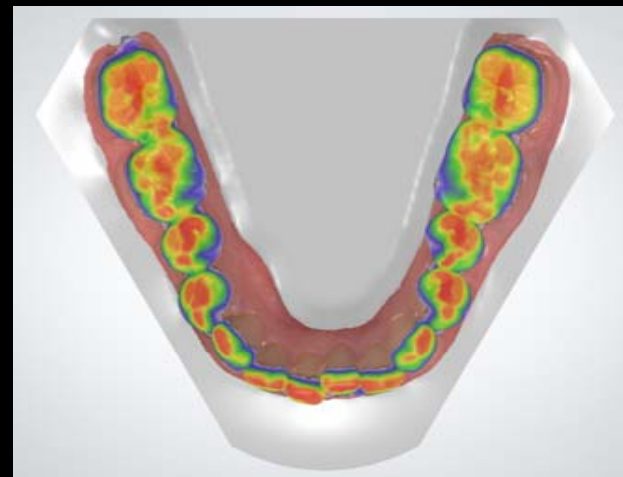
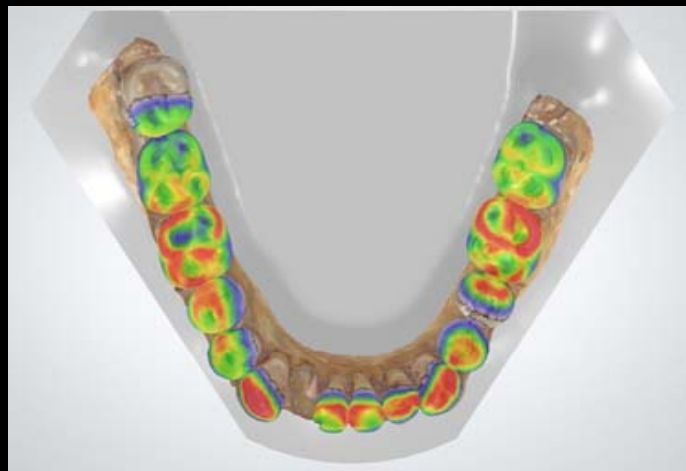

OPI ARCH

>

CONTEMPORARY ARCH

Mandibular contacts

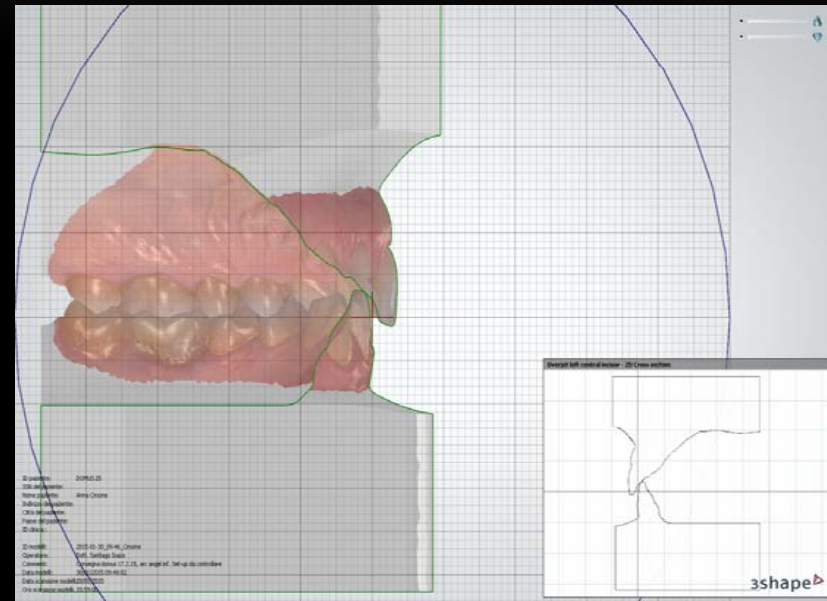
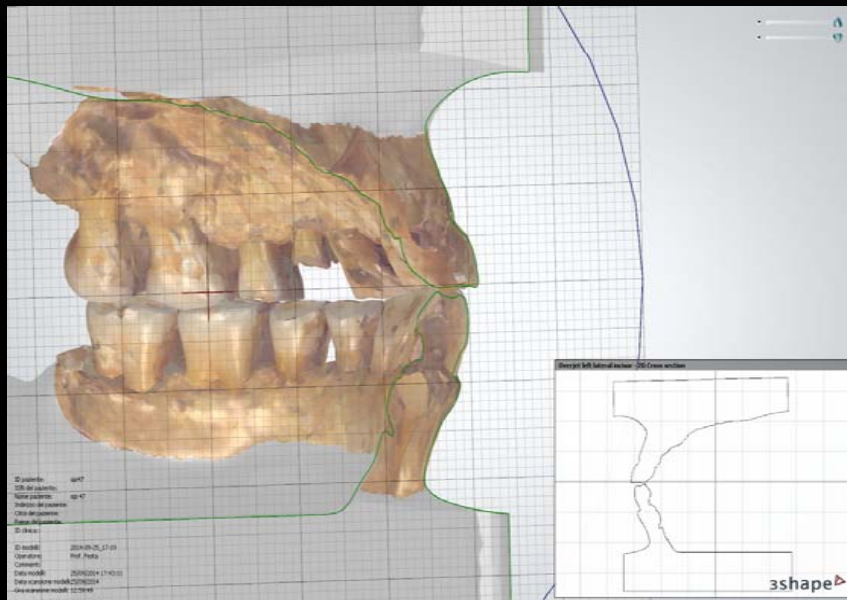


# OPI ARCH

>

# CONTEMPORARY ARCH

Overjet and overbite compared

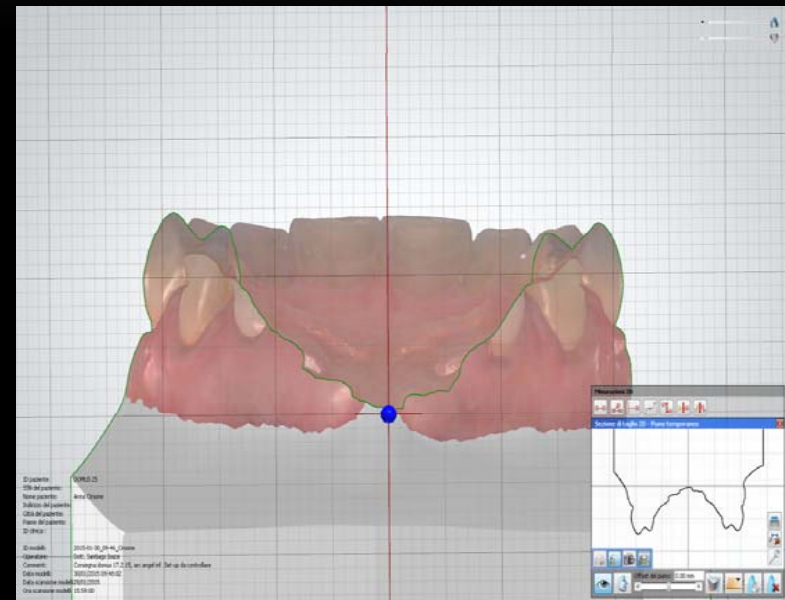
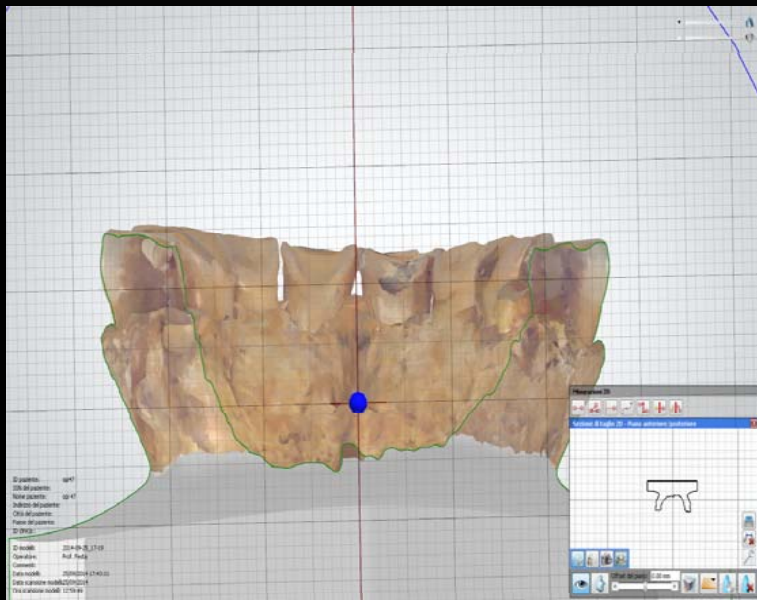


# OPI ARCH

>

# CONTEMPORARY ARCH

Morphological difference of upper premolars

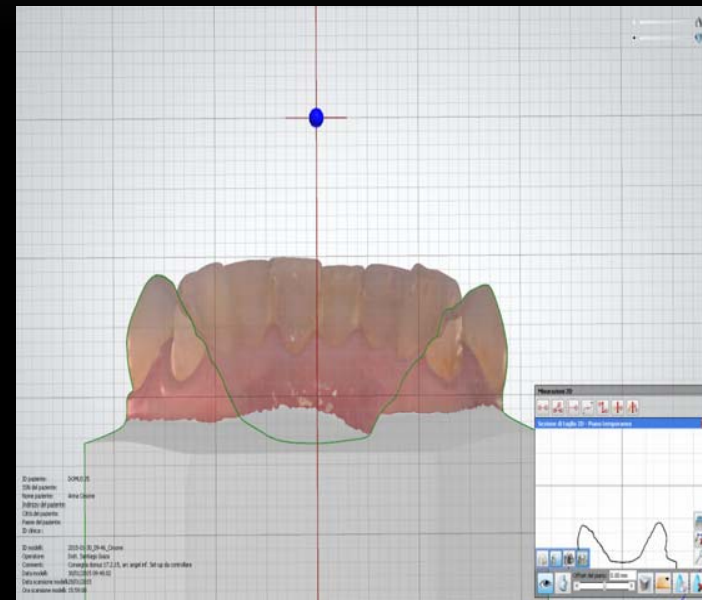
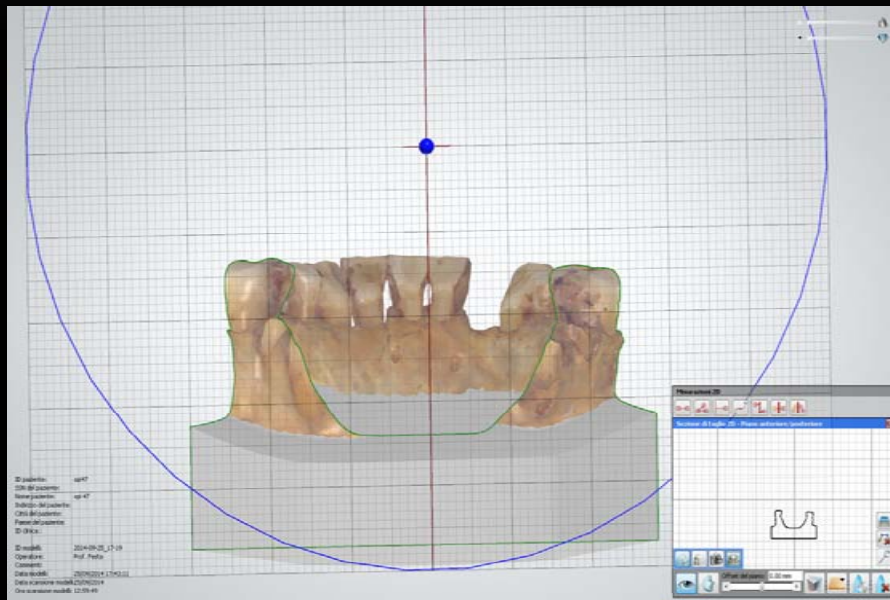


# OPI ARCH

>

# CONTEMPORARY ARCH

Morphological difference of lower premolars

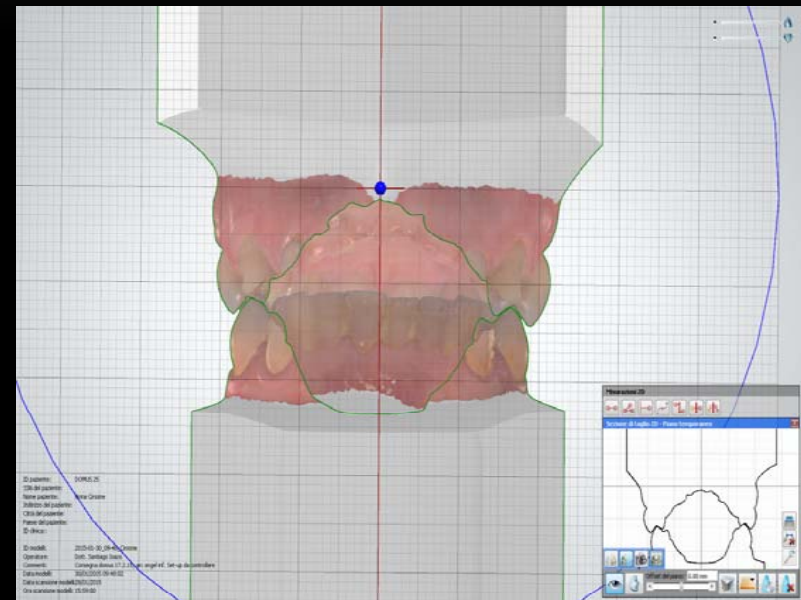
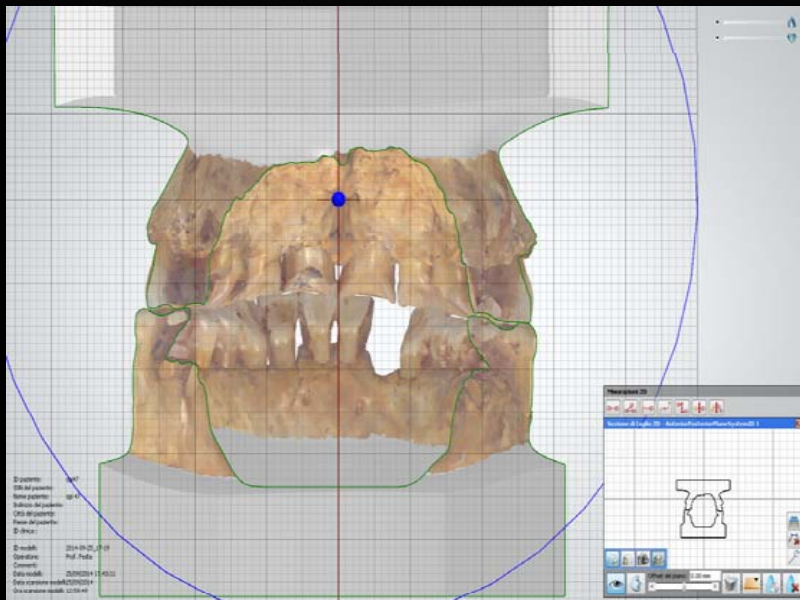


# OPI ARCH

>

# CONTEMPORARY ARCH

Intermaxillary relationship premolars

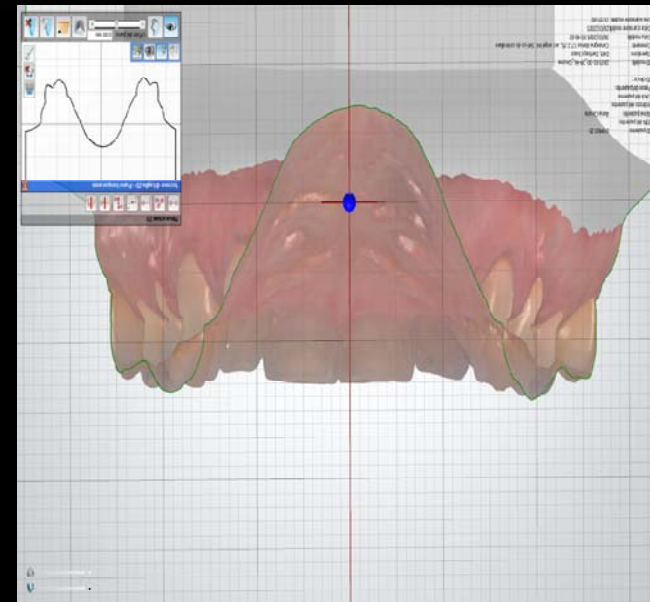
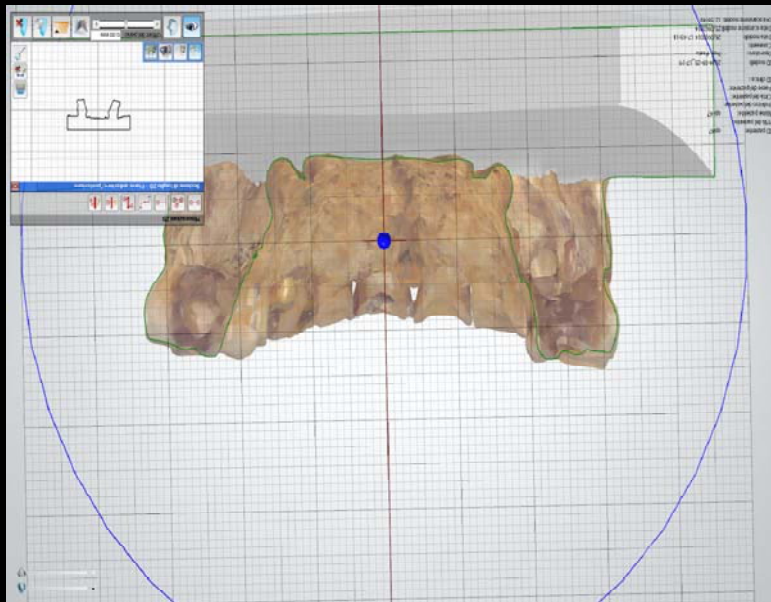


OPI ARCH

>

CONTEMPORARY ARCH

Morphological difference of the upper first molars

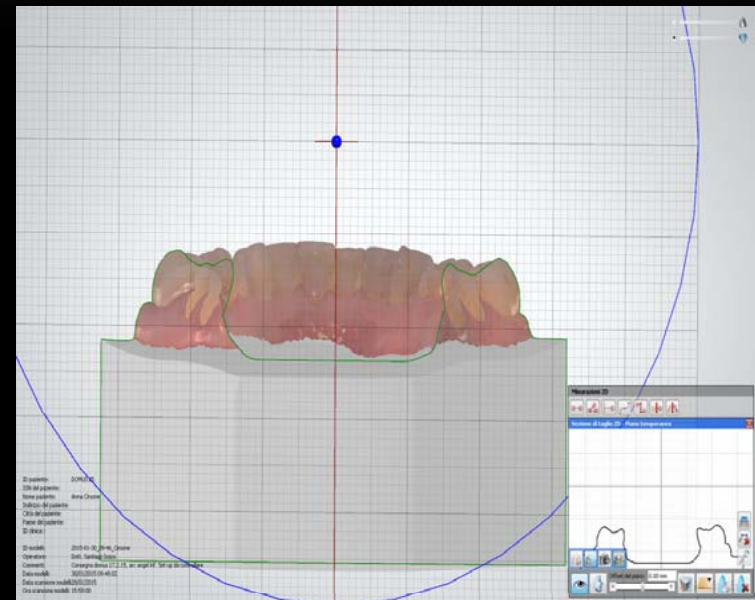
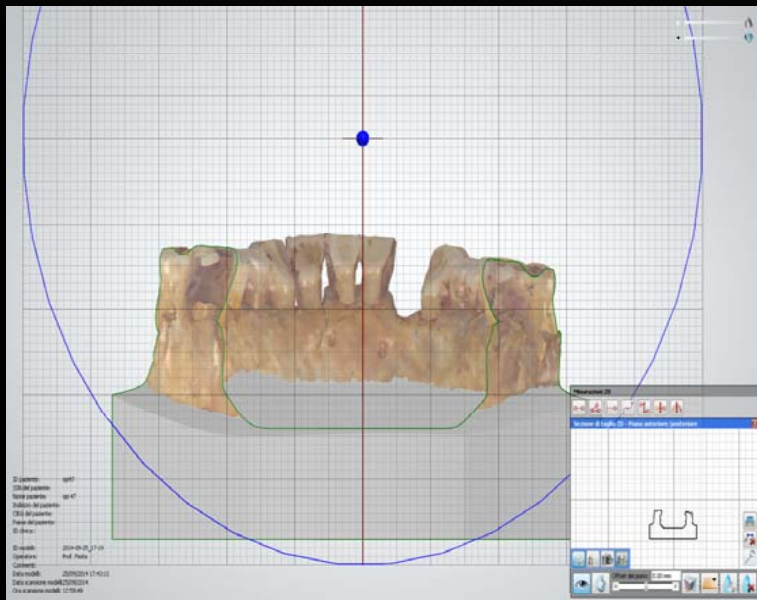


# OPI ARCH

>

# CONTEMPORARY ARCH

Morphological difference of the lower first molars

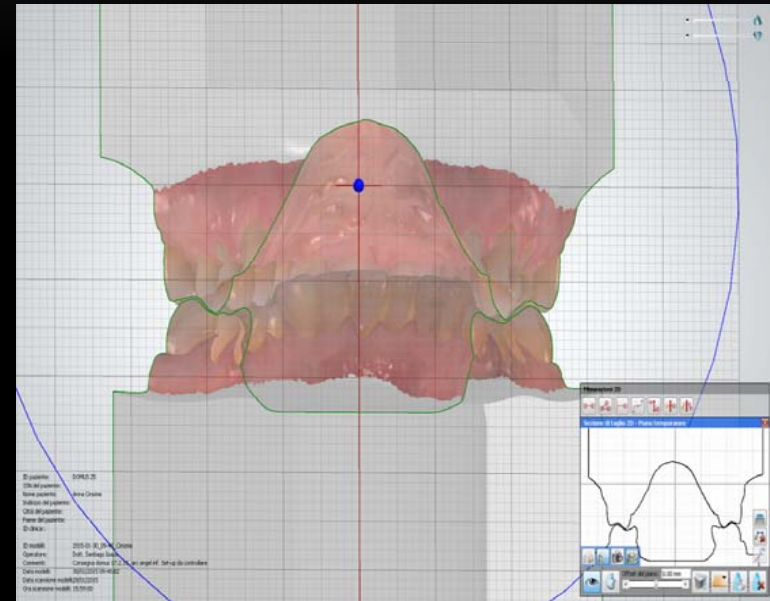
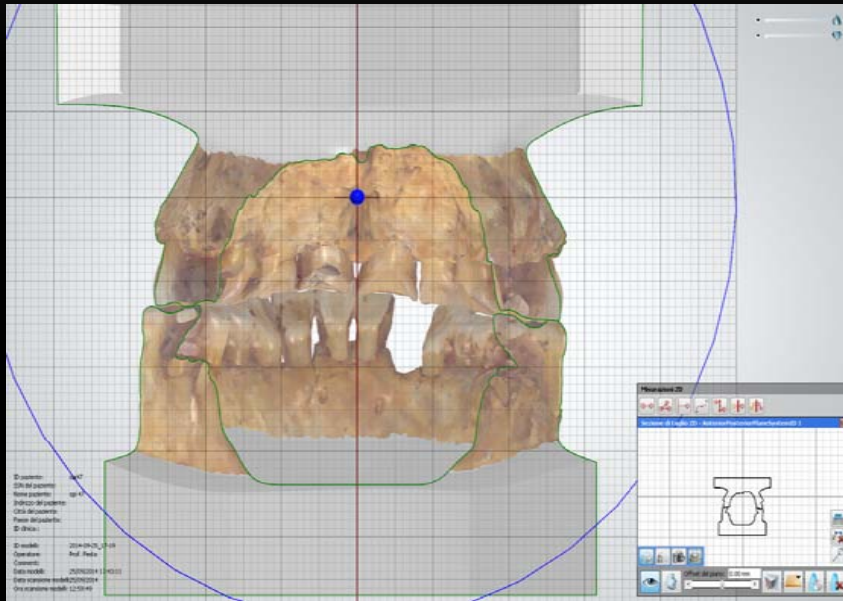


# OPI ARCH

>

# CONTEMPORARY ARCH

First molars intermaxillary relationship





# TMJ/ORTHODONTICS CLINICAL CHART DOLPHIN 3D

- Transition from 2D to 3D Orthodontics
- 1) Segmentation
- 2) Orientation
- 3) Virtual 2D X-Rays development (lateral>orthophantomography>TMJ>cross sections>postero-anterior>upper arch submento-vertex>lower arch submento-vertex
- Cephalometrics > Transition to 3D cephalometrics
- 4) Virtual 2D
- 5) Virtual 3D muscles Dissections: Right Masseter>Left Masseter

**INTRAORAL SCANNERS**      Diagnosis Genomic  
3D Appliances

---

# 3D Appliance

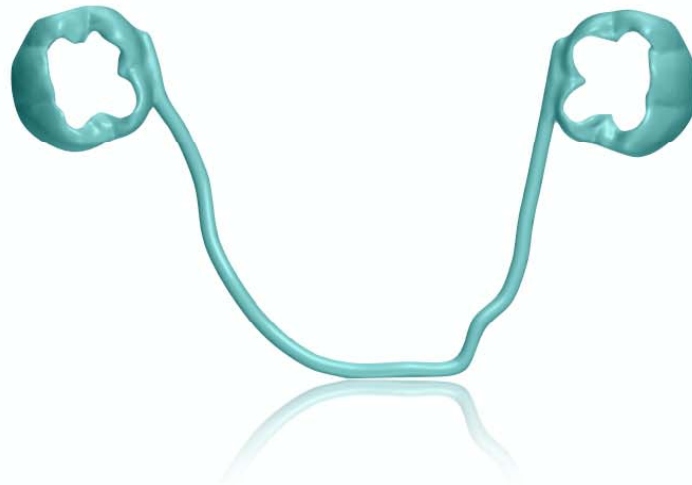
3D Appliance

Sdt. Stefano Negrini

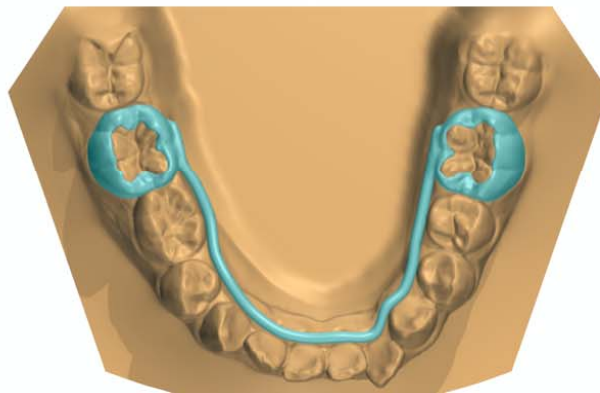
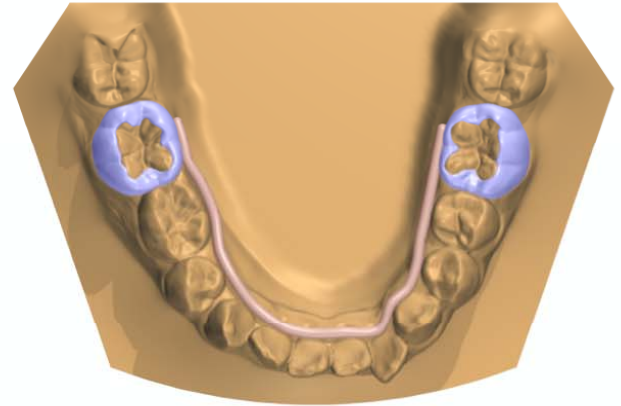
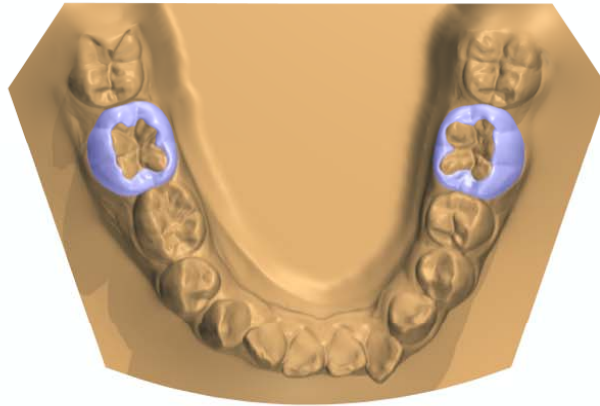
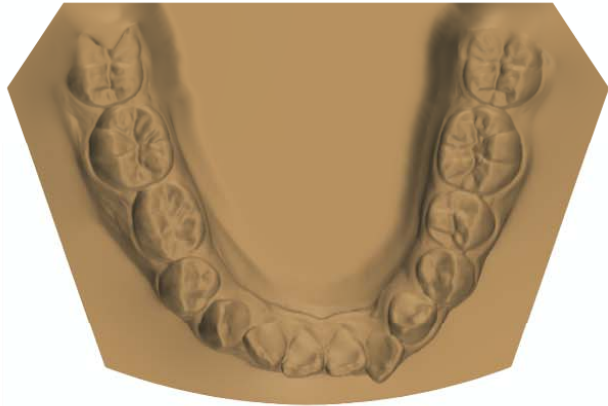---

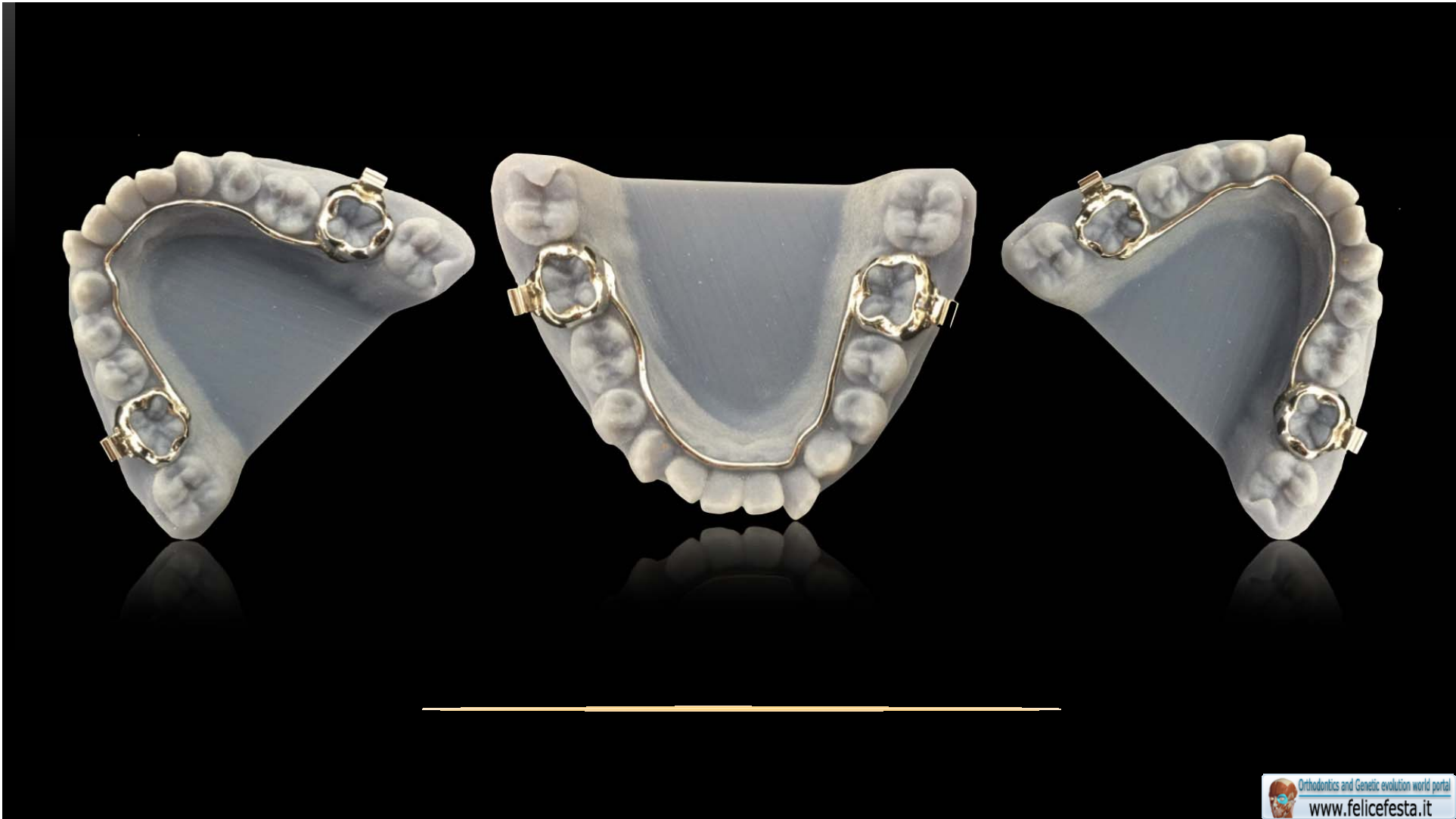


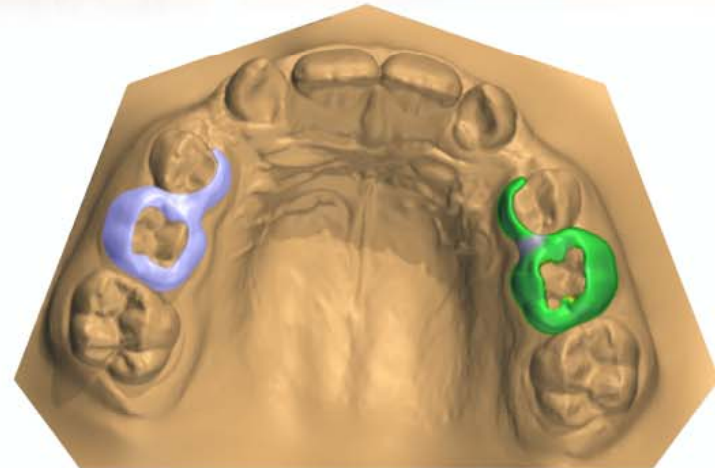

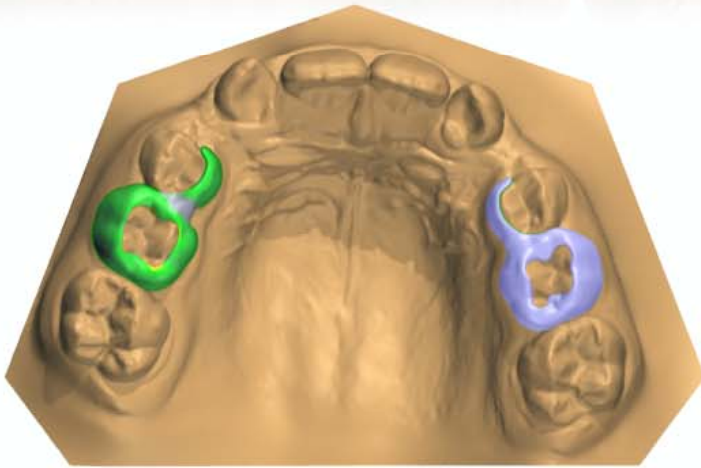
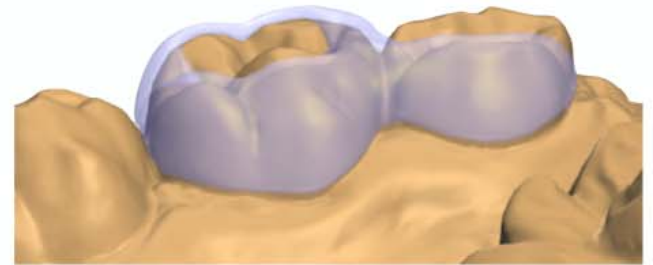
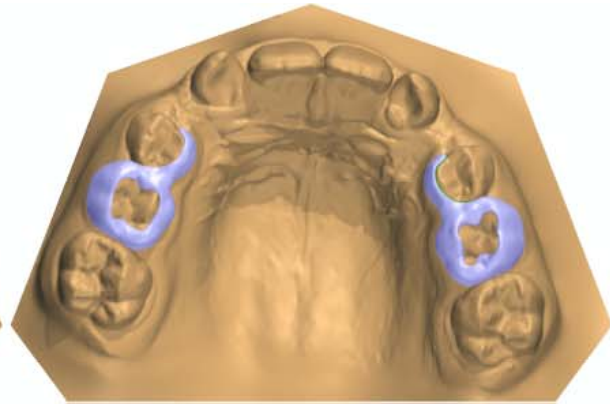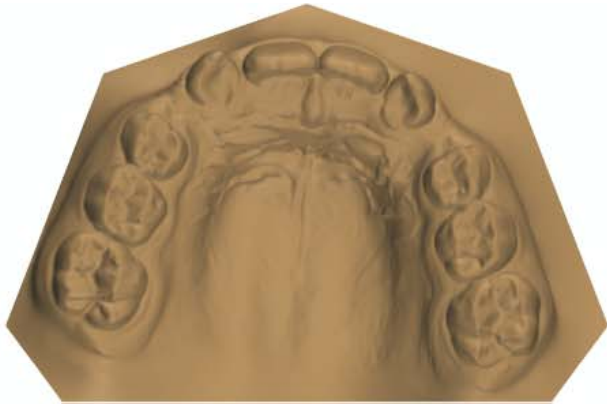
# Lingual Arch

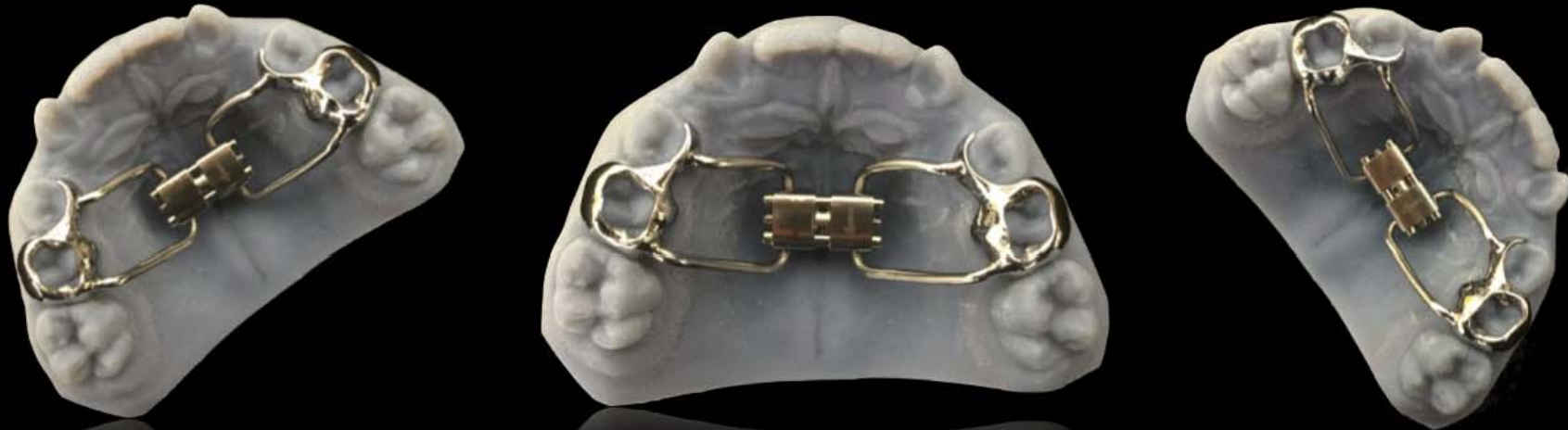

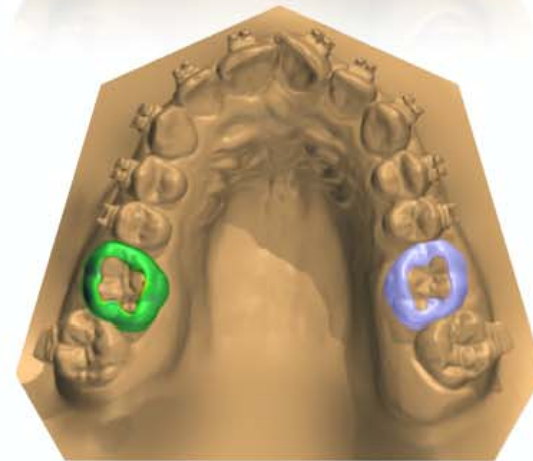

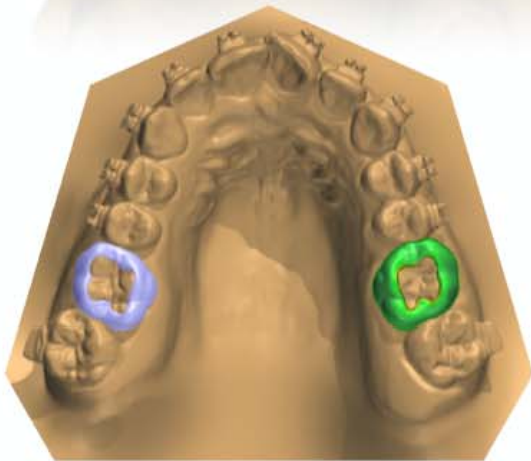
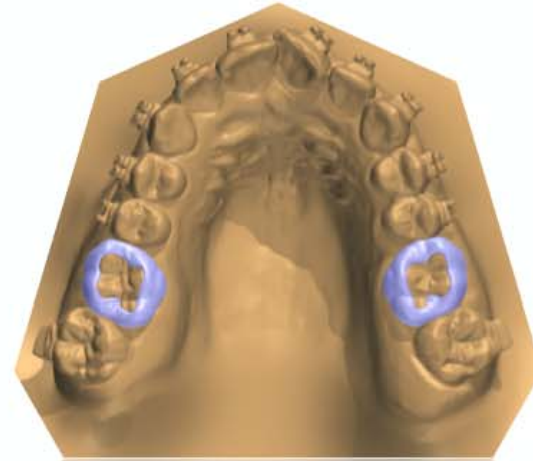
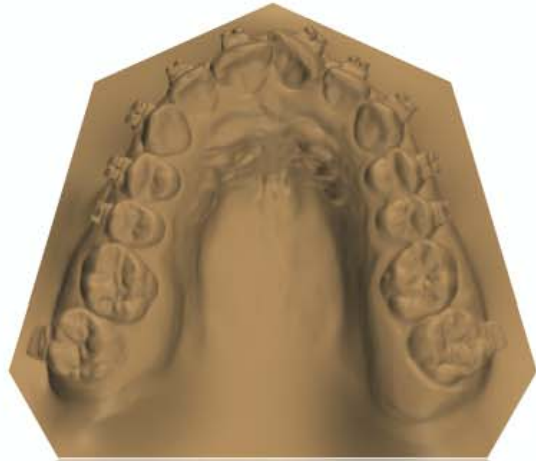\_\_\_\_\_



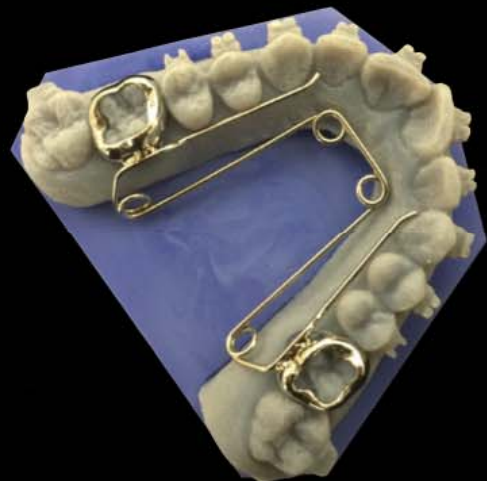
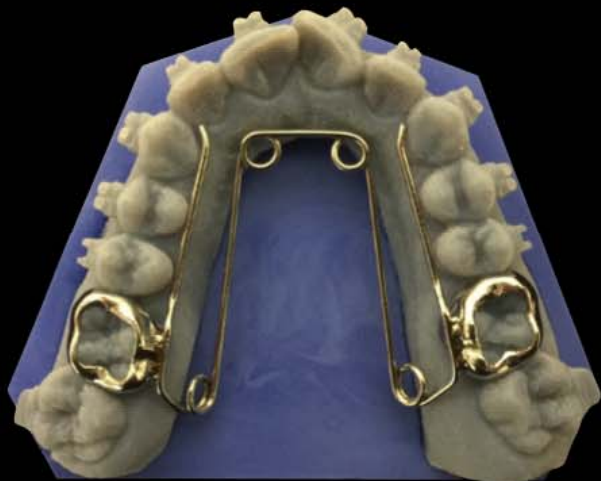
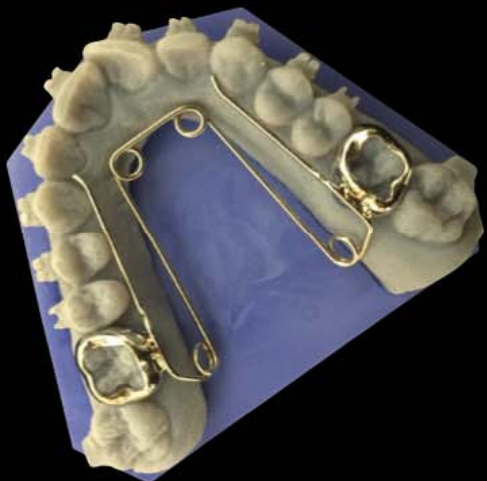










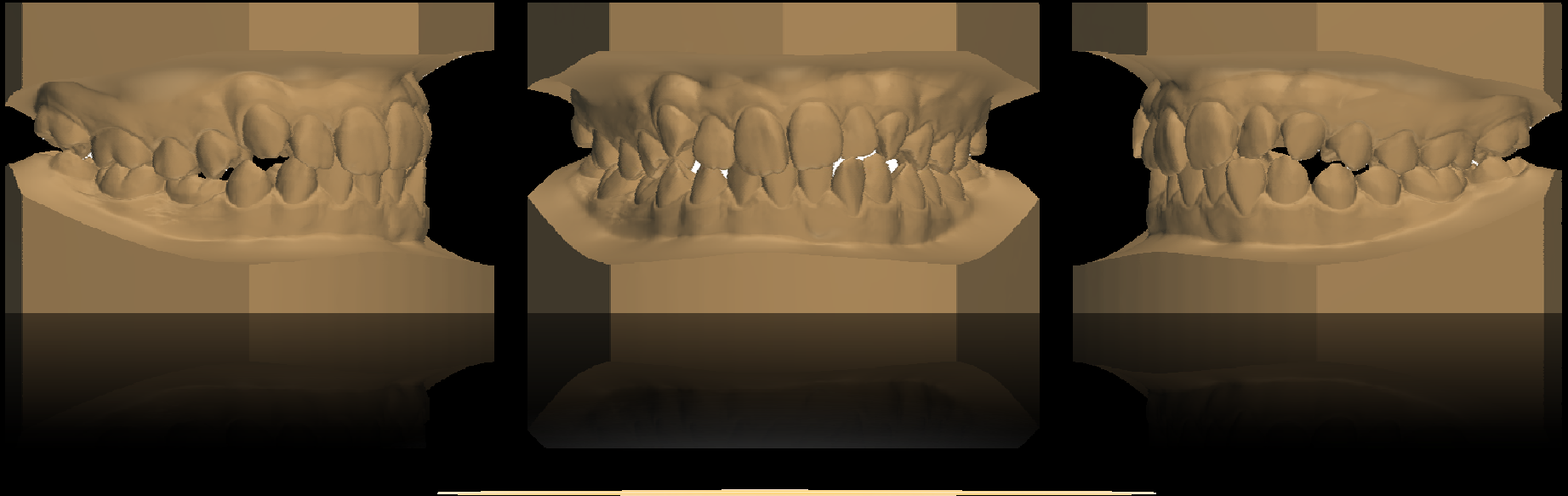# 3D APPLIANCE

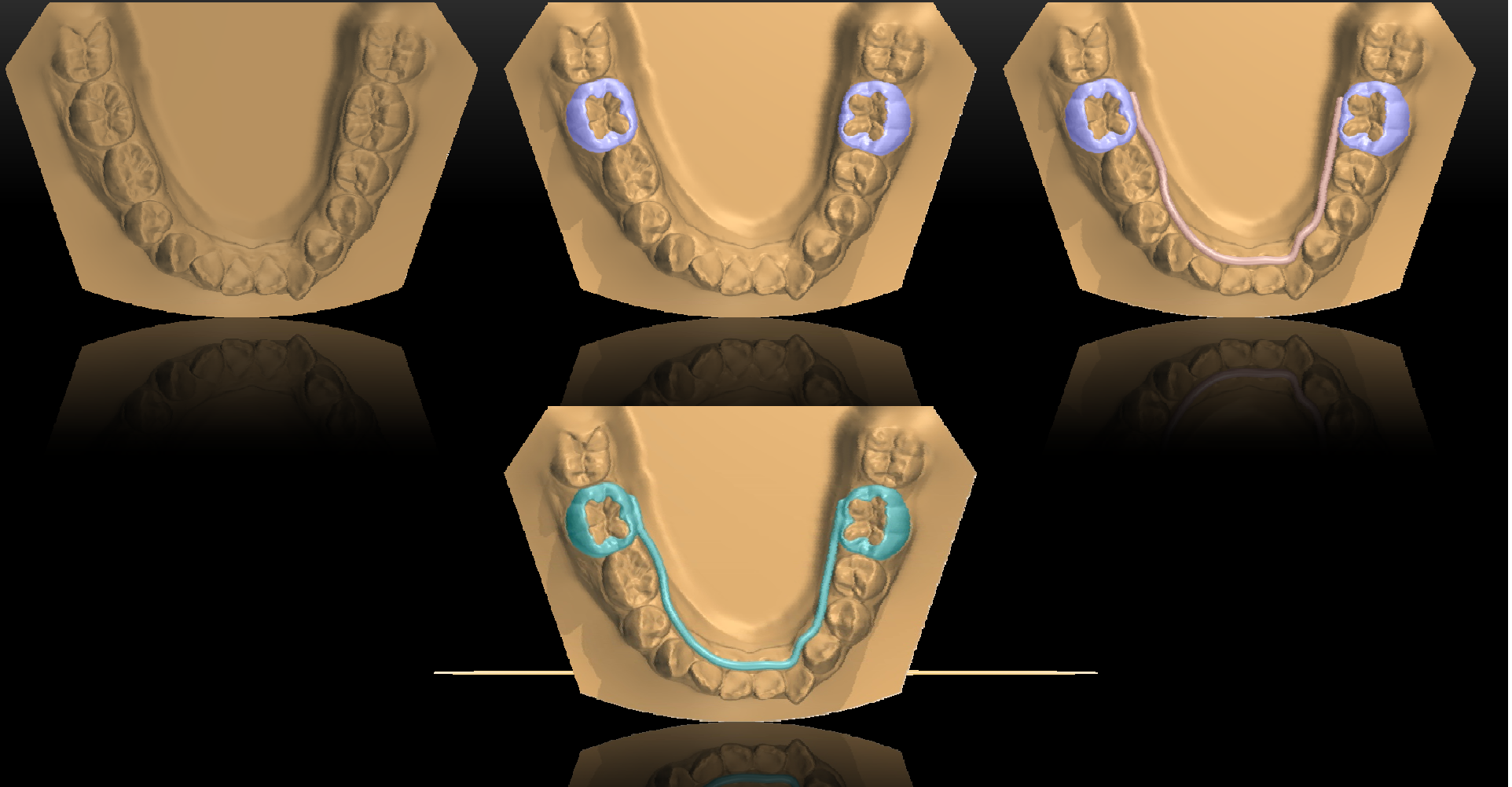
Dr. Karin Becktor Sdt. Stefano Negrini

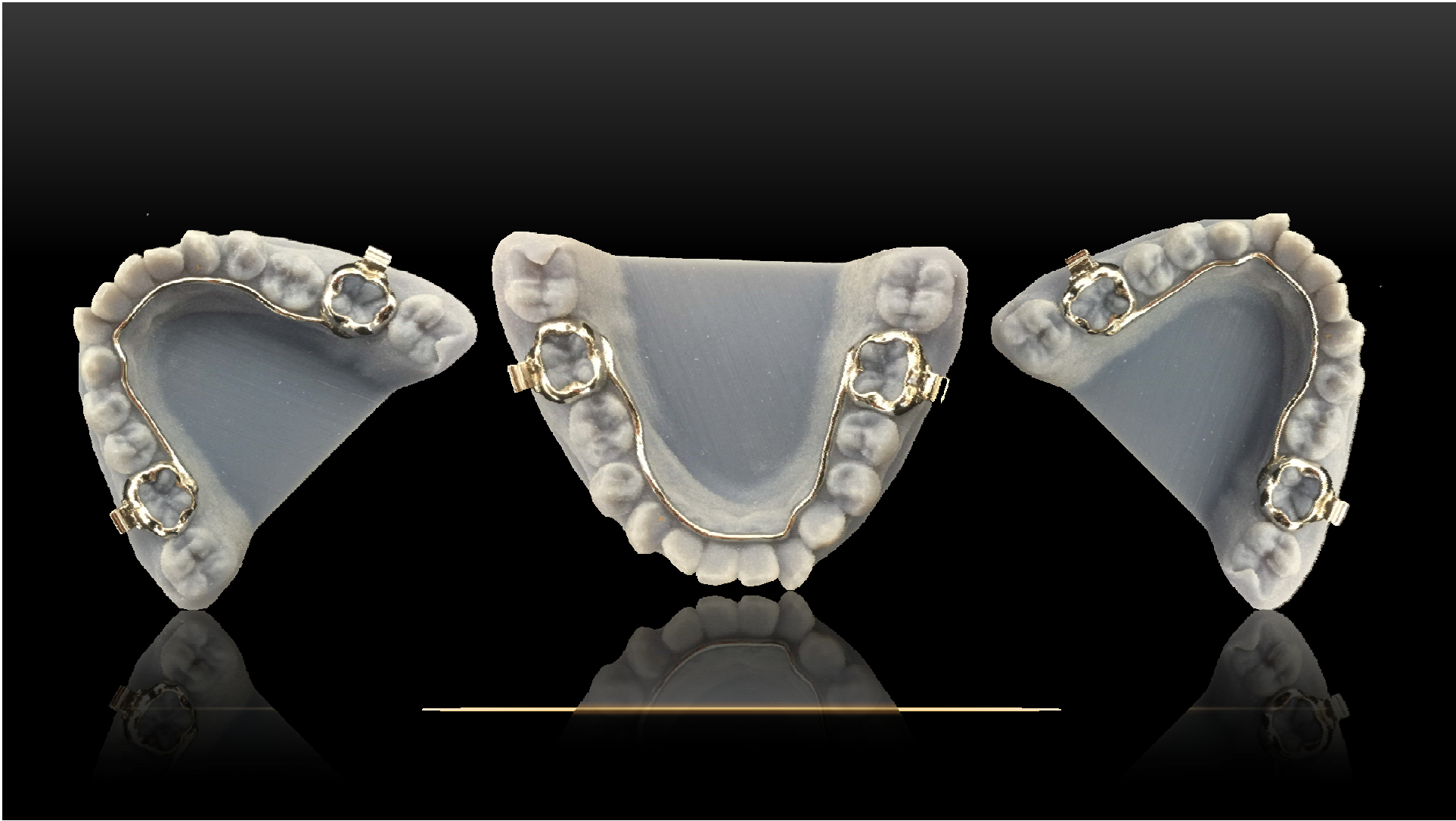
---

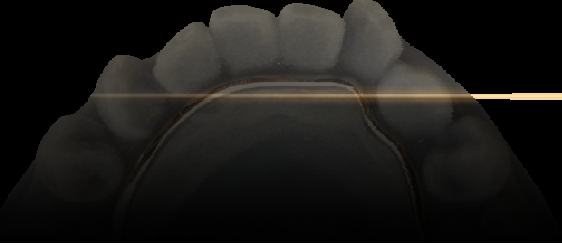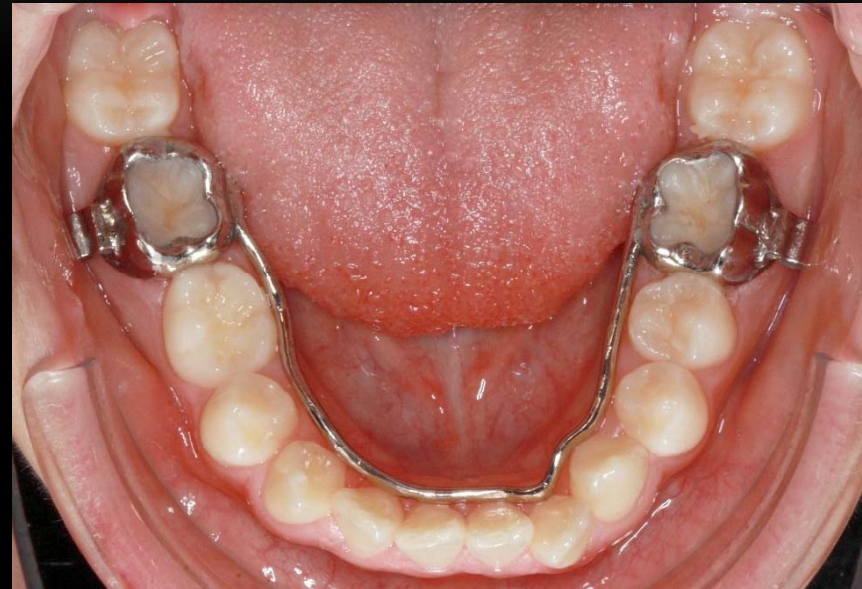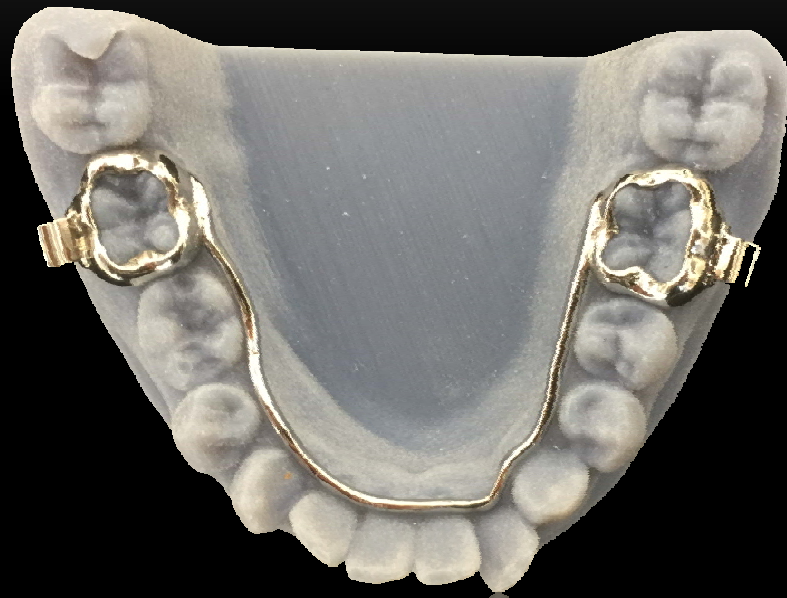
LINGUAL ARCH

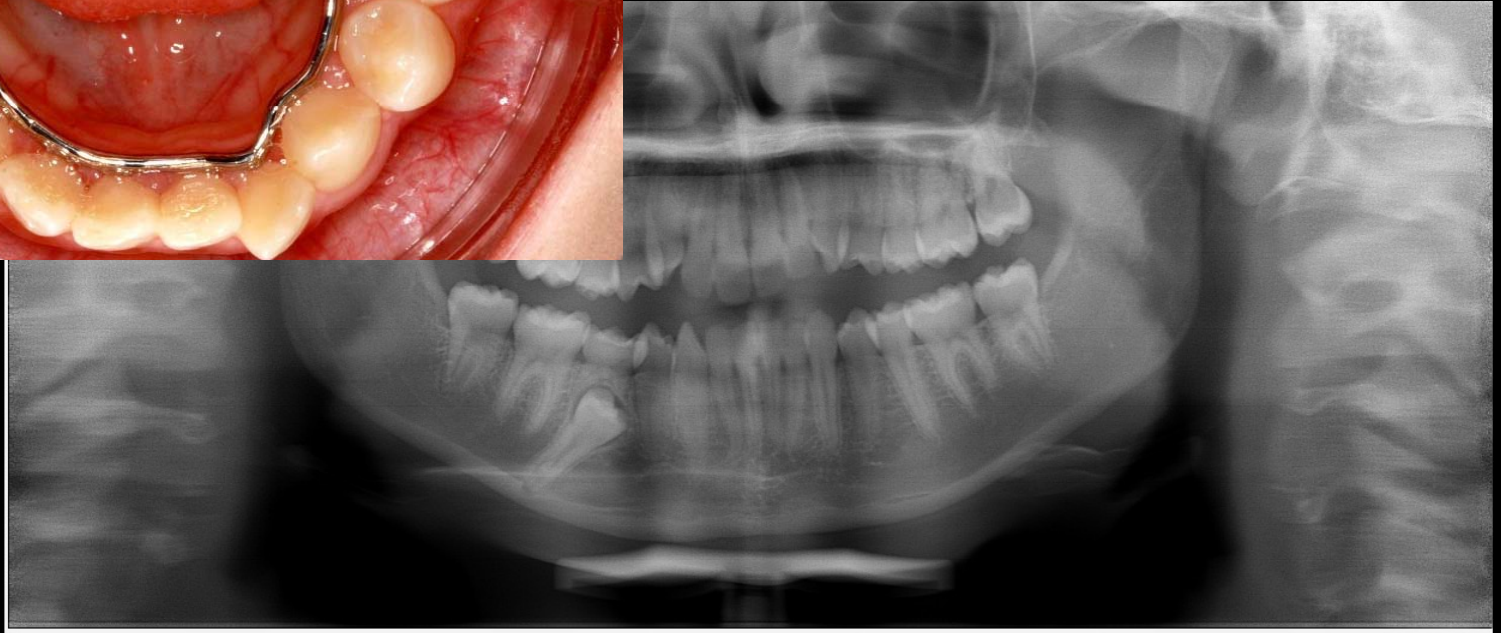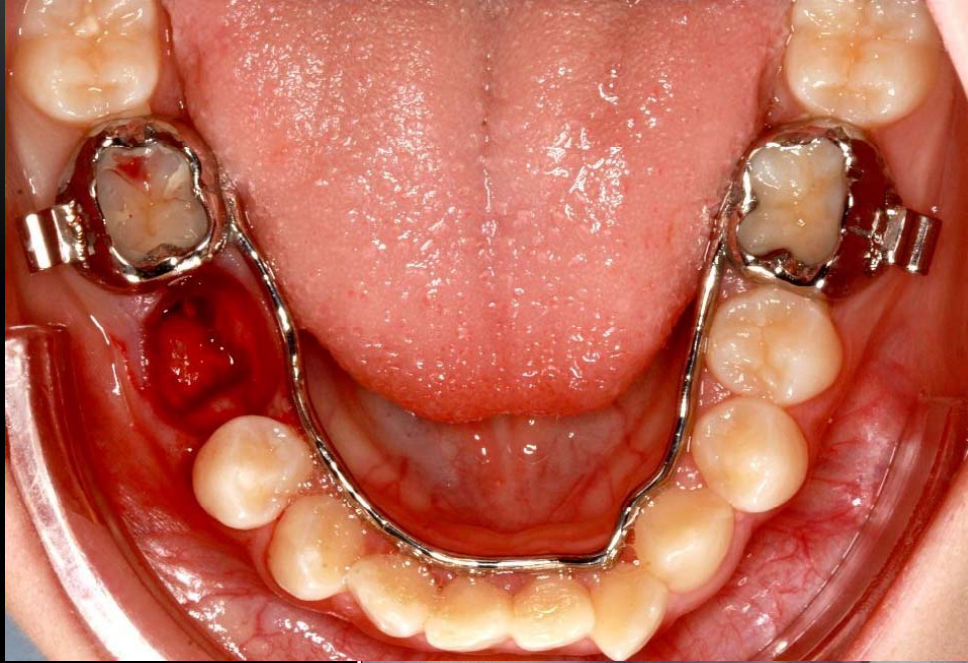






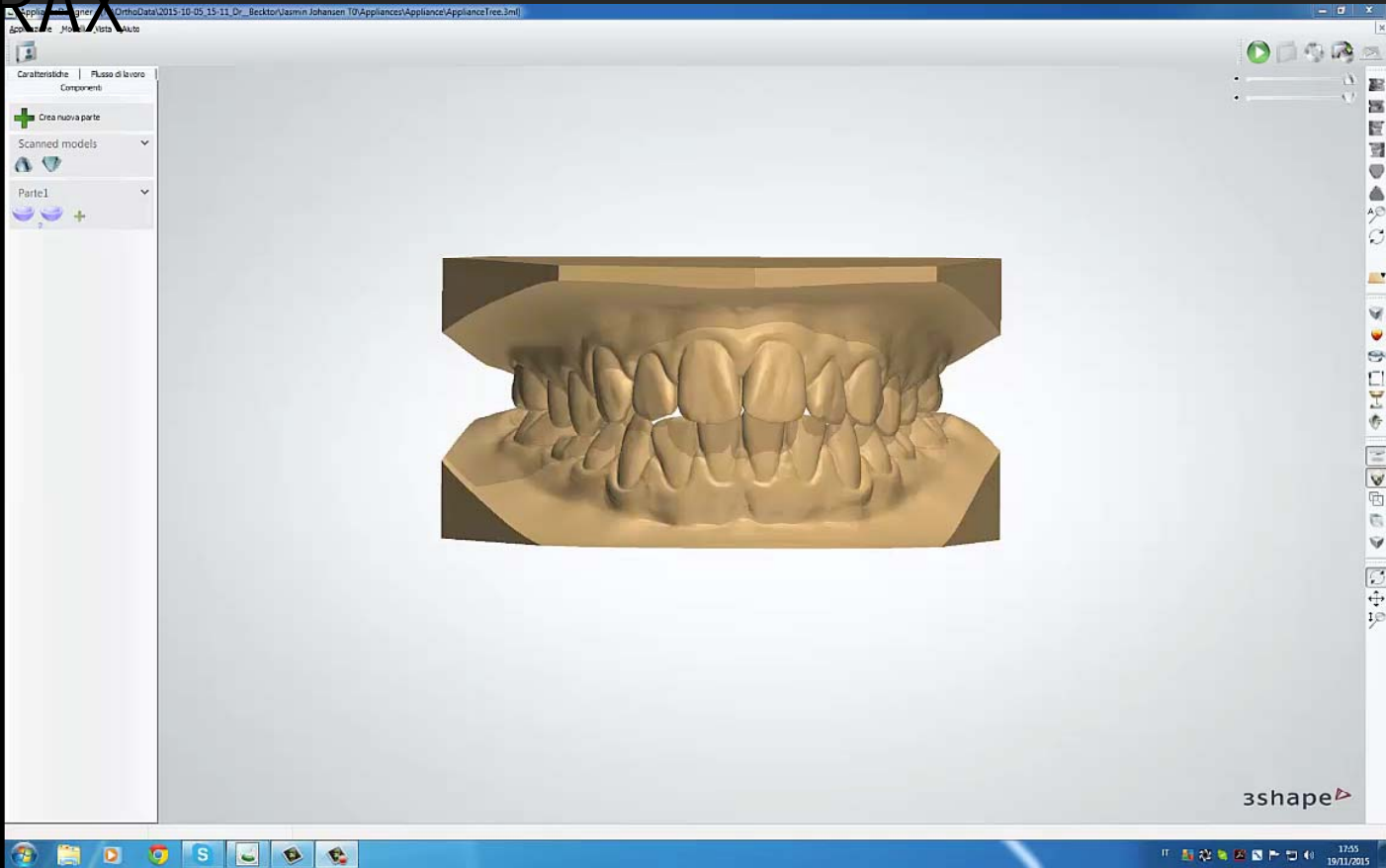


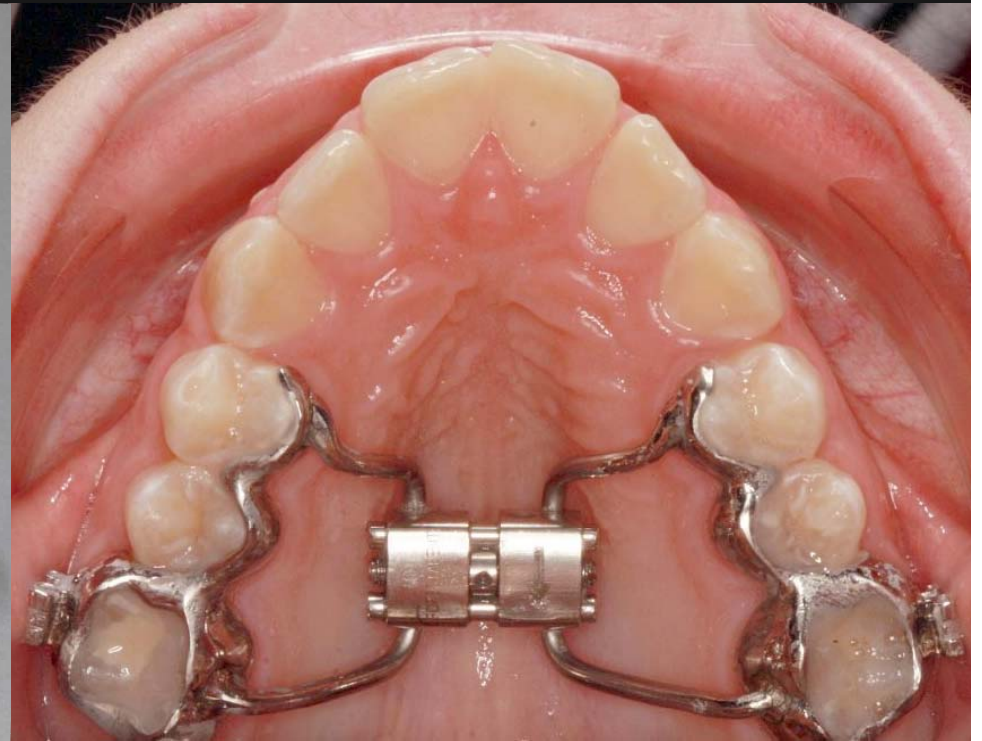

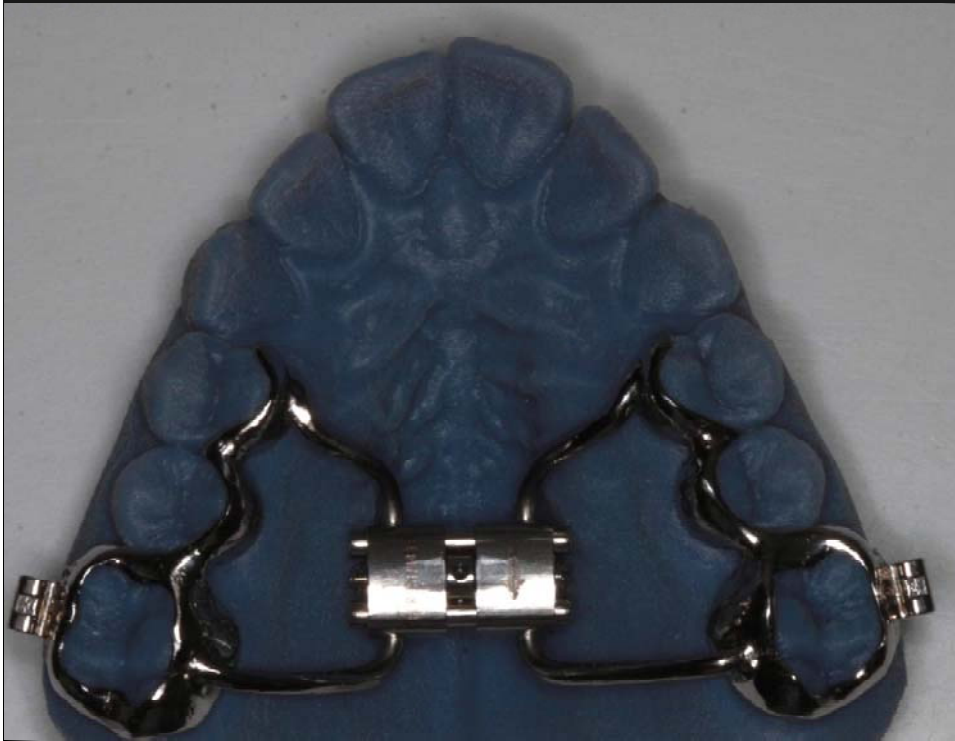


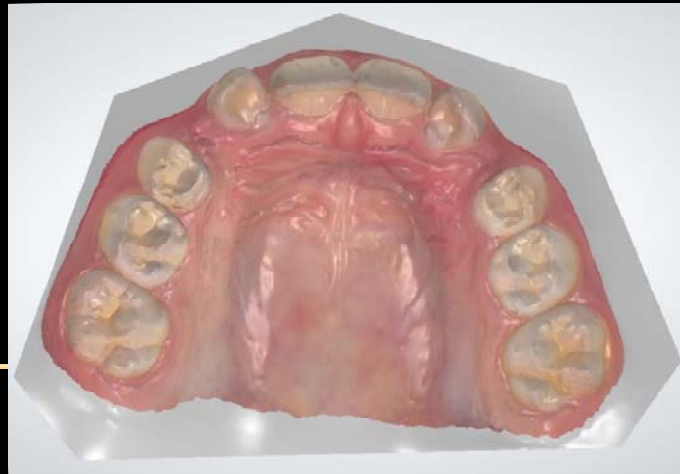
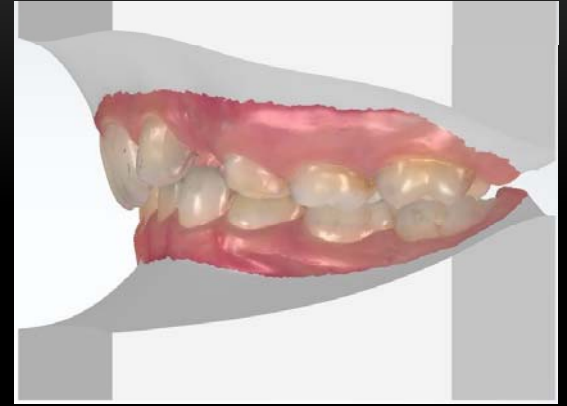
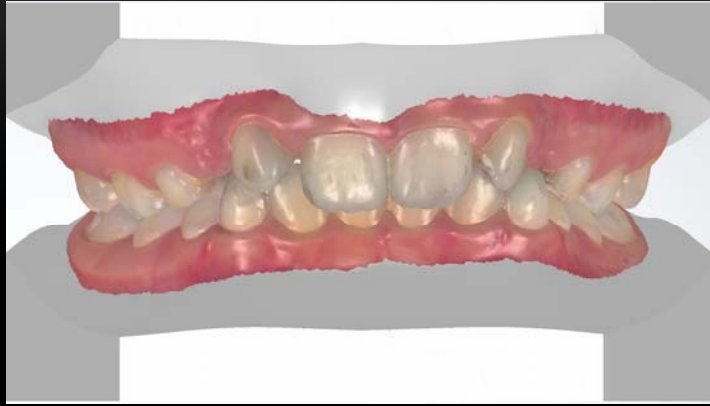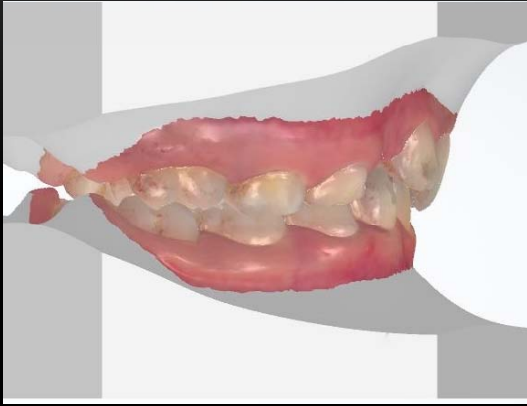


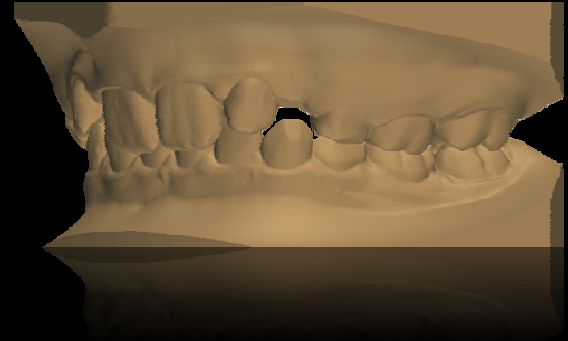
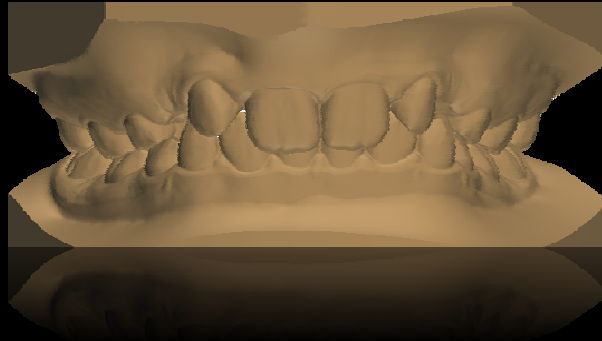
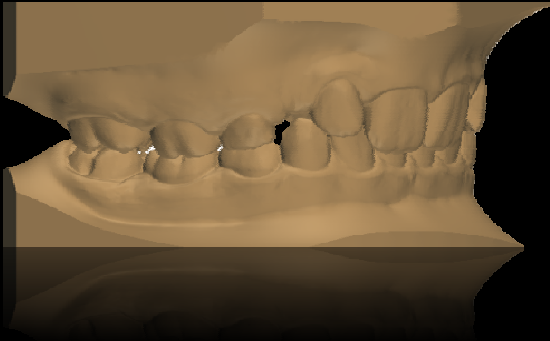
# HVRAX



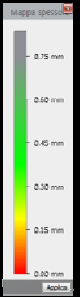
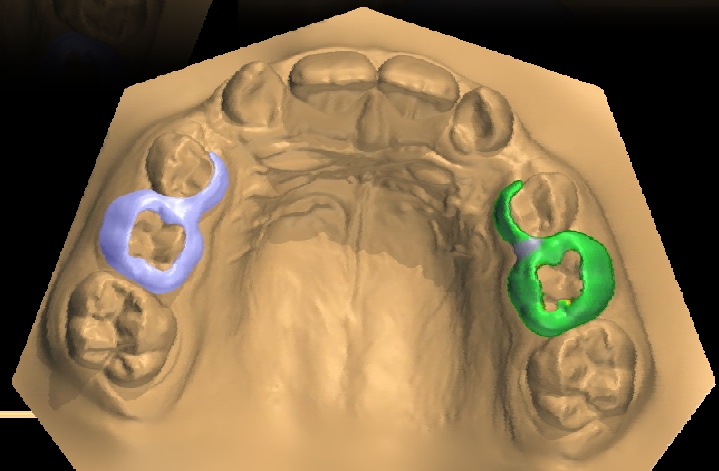
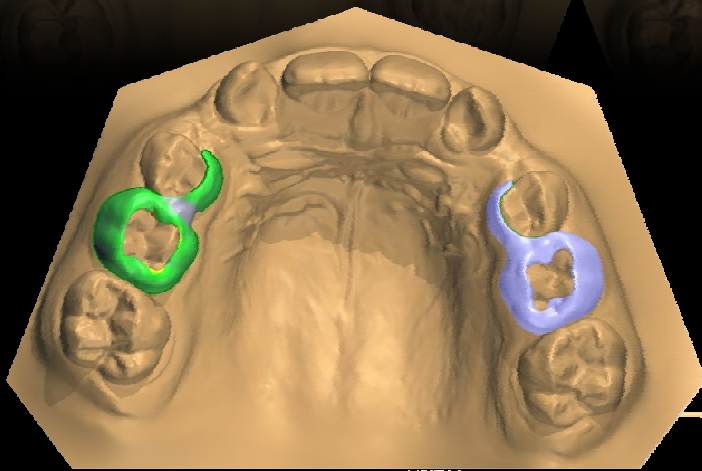
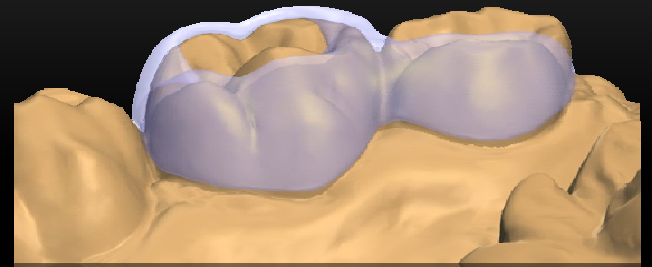
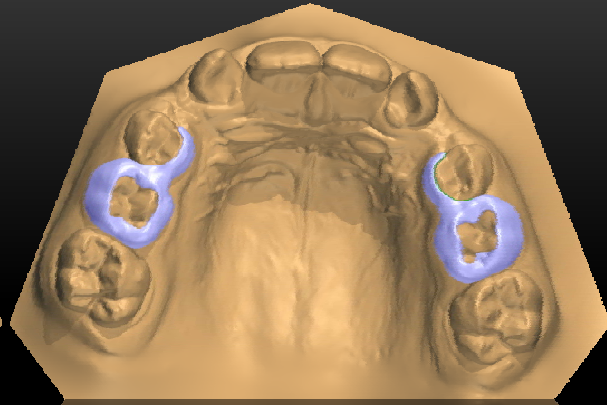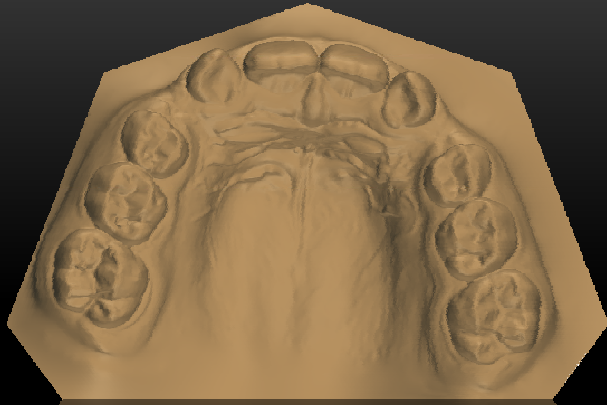


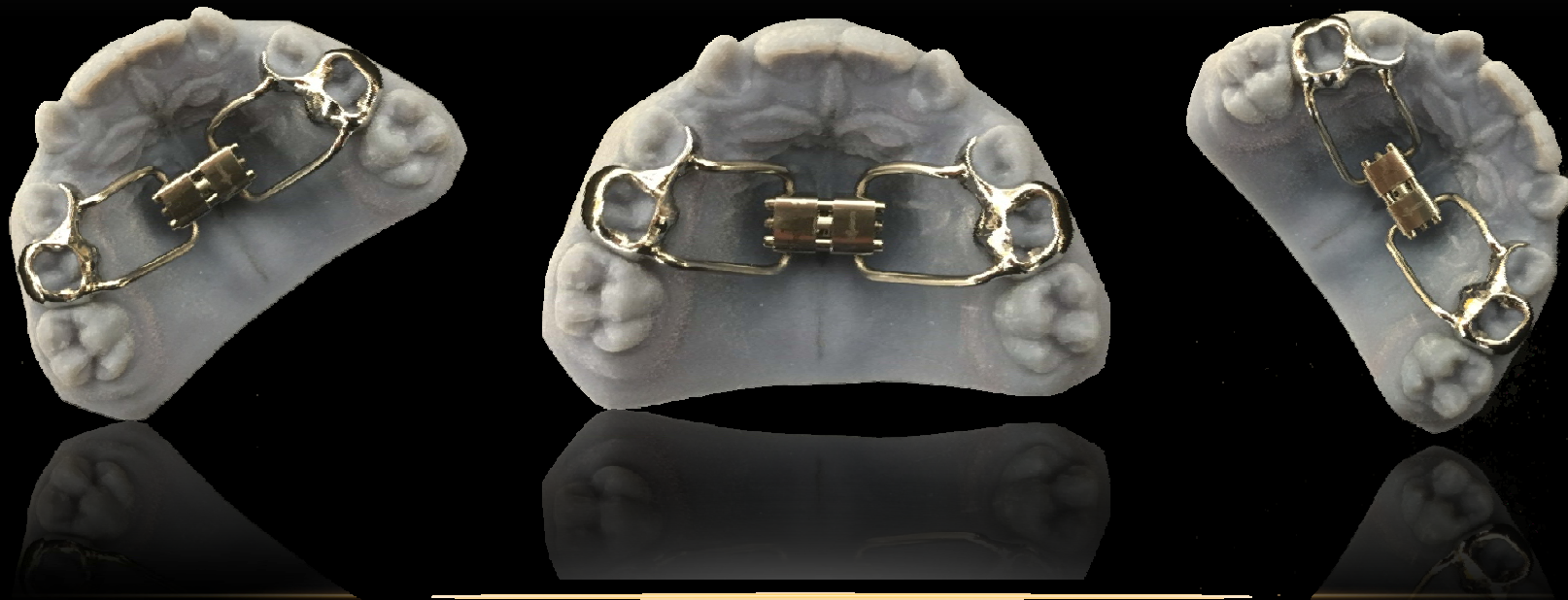# HYRAX

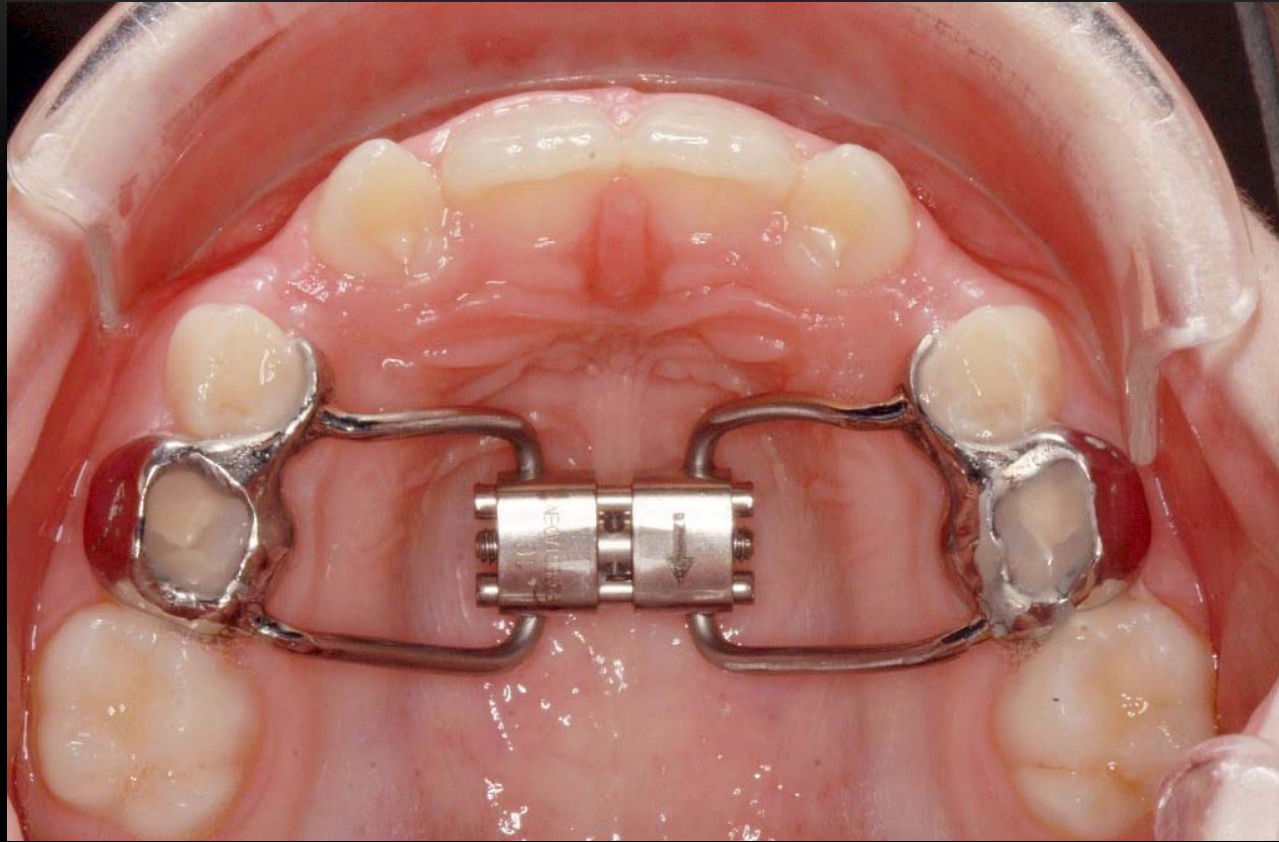


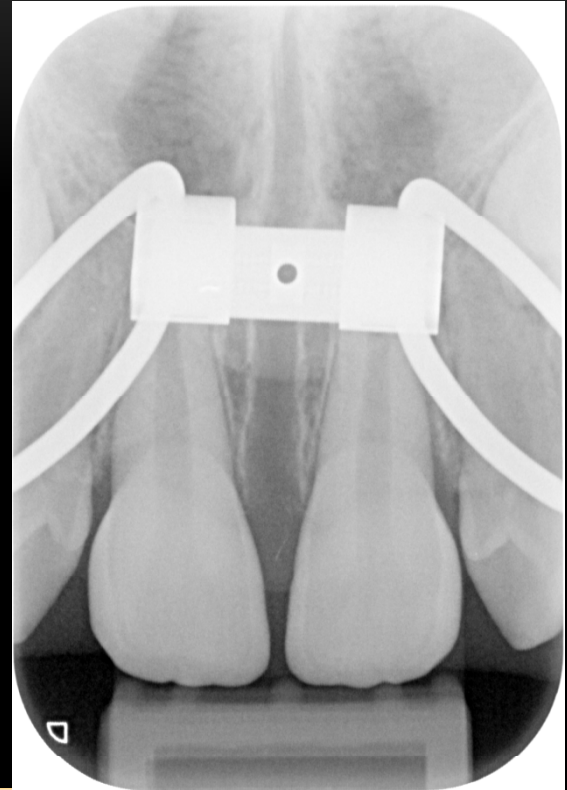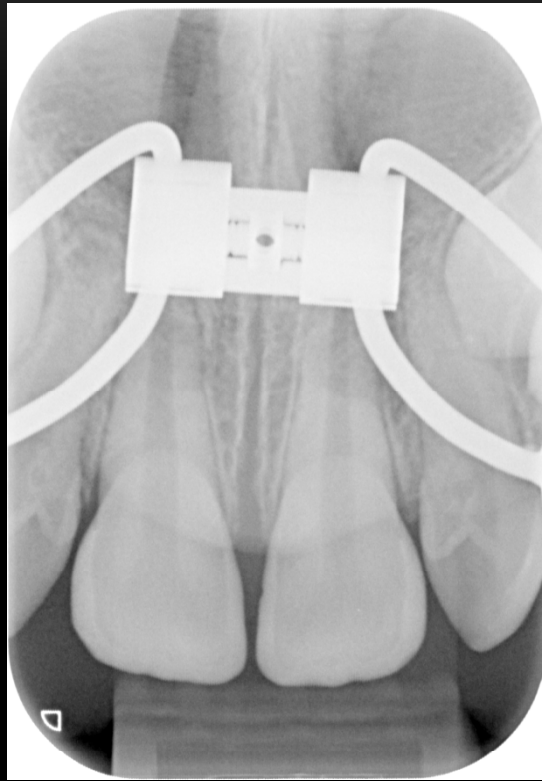
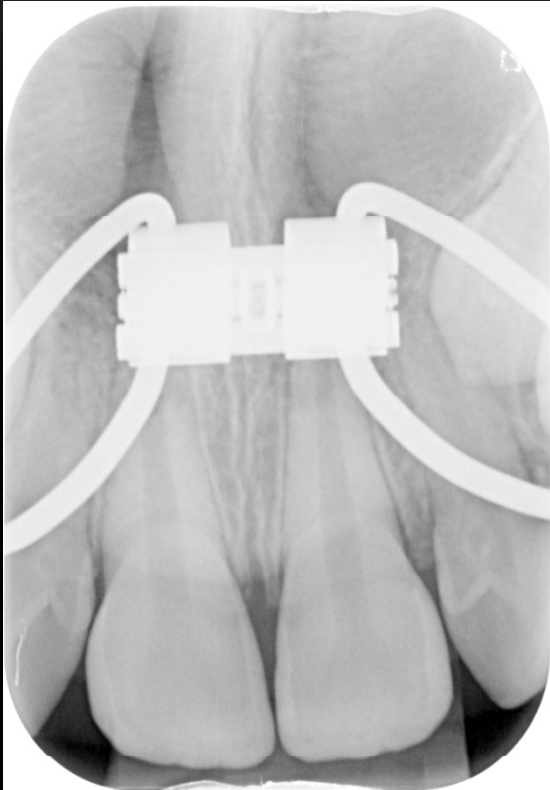


\_\_\_\_\_







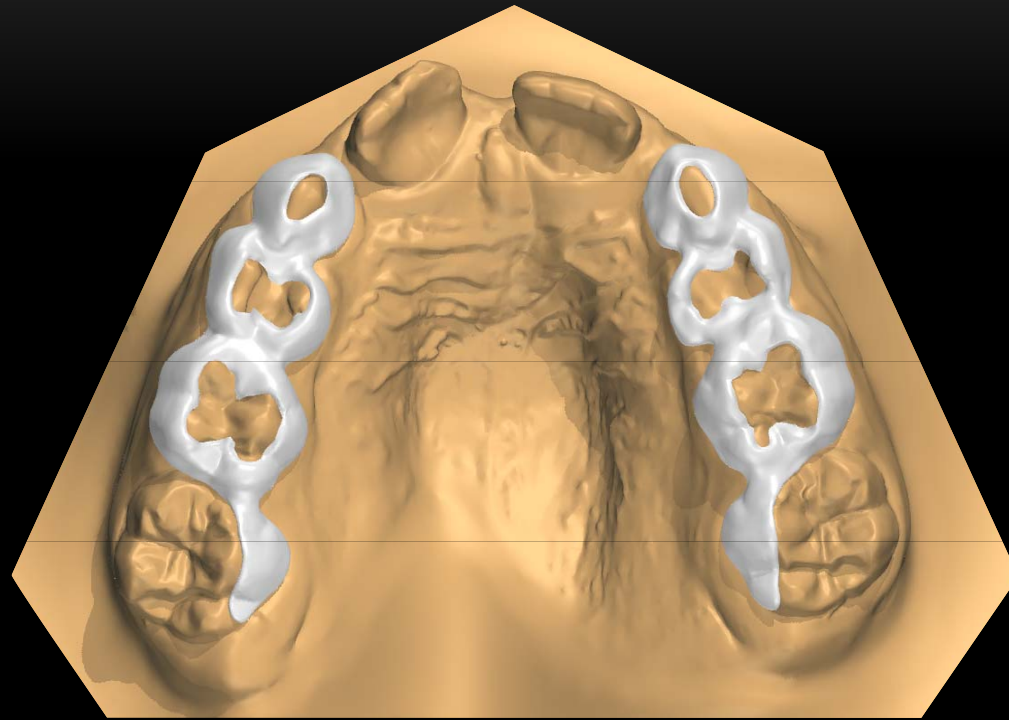


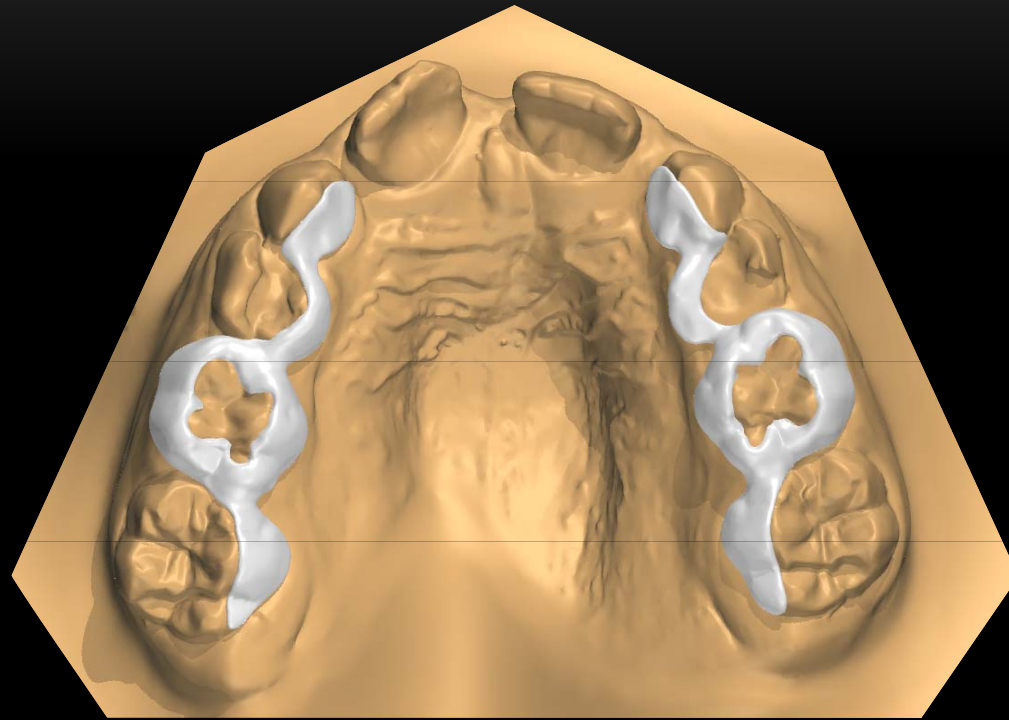


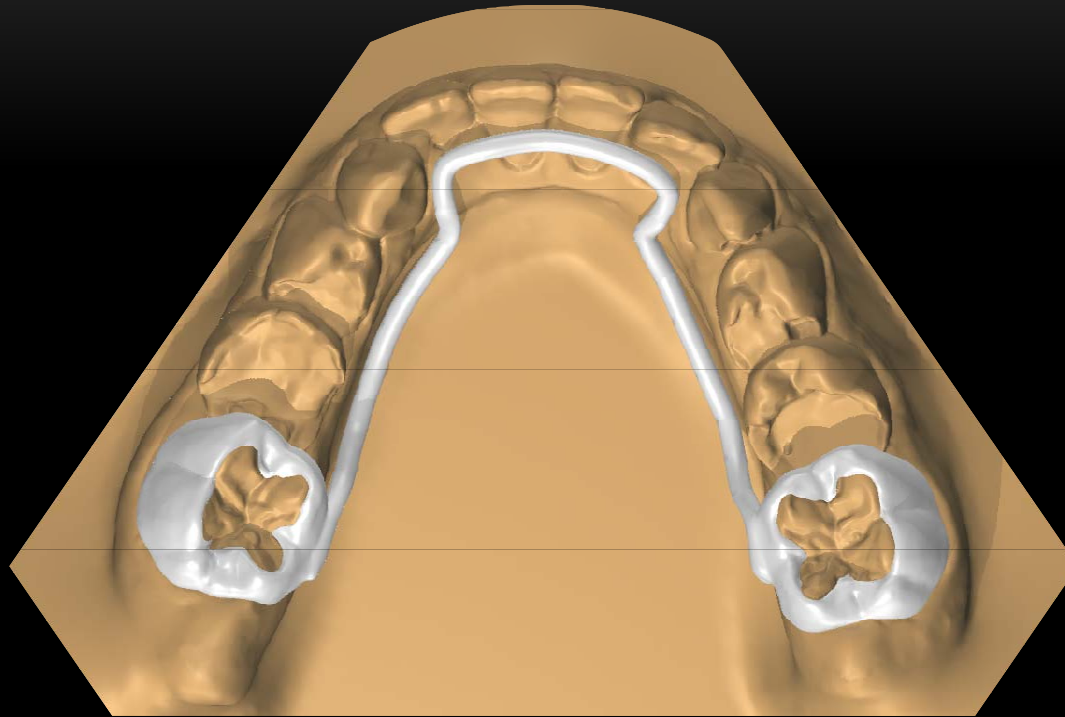
# RPE-LINGUAL ARCH TITANIUM

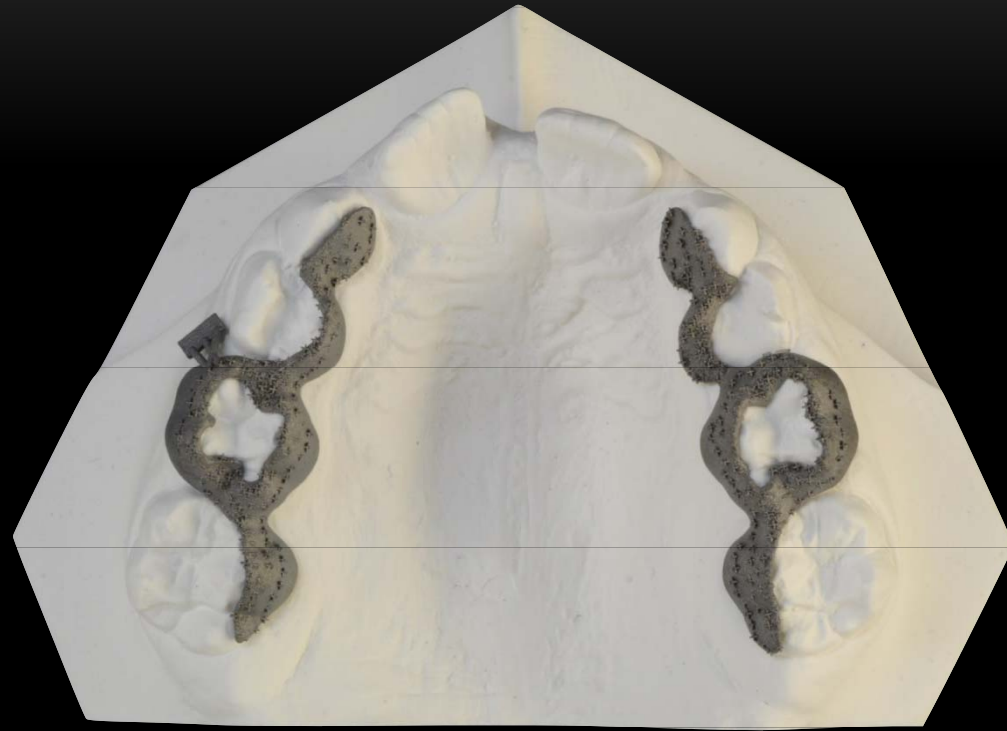Sdt. Riccardo Palla Sdt. Stefano Nergini

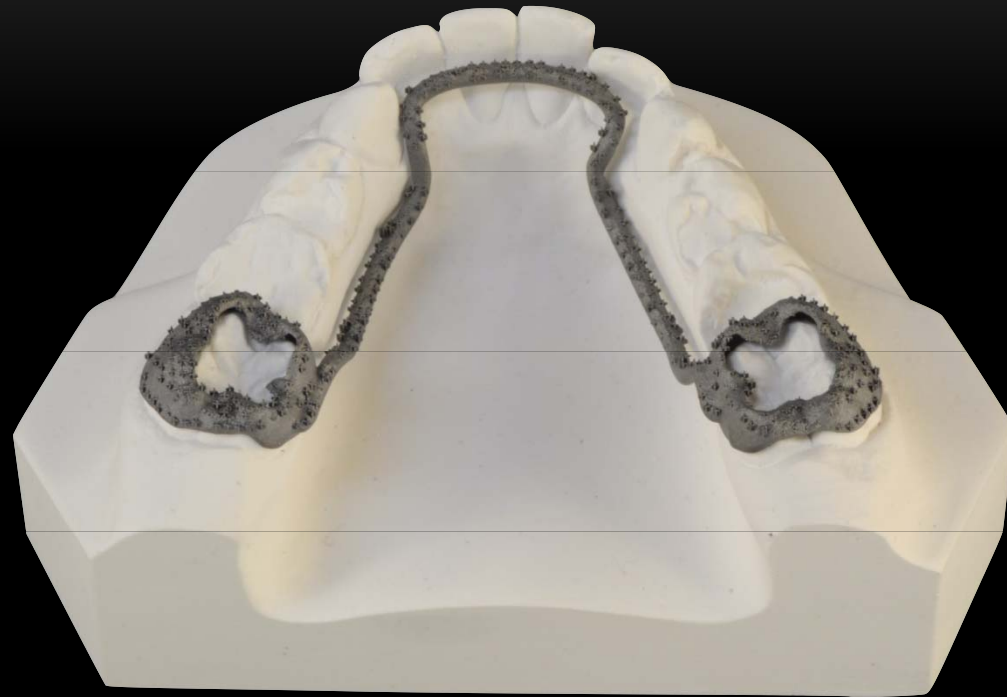---




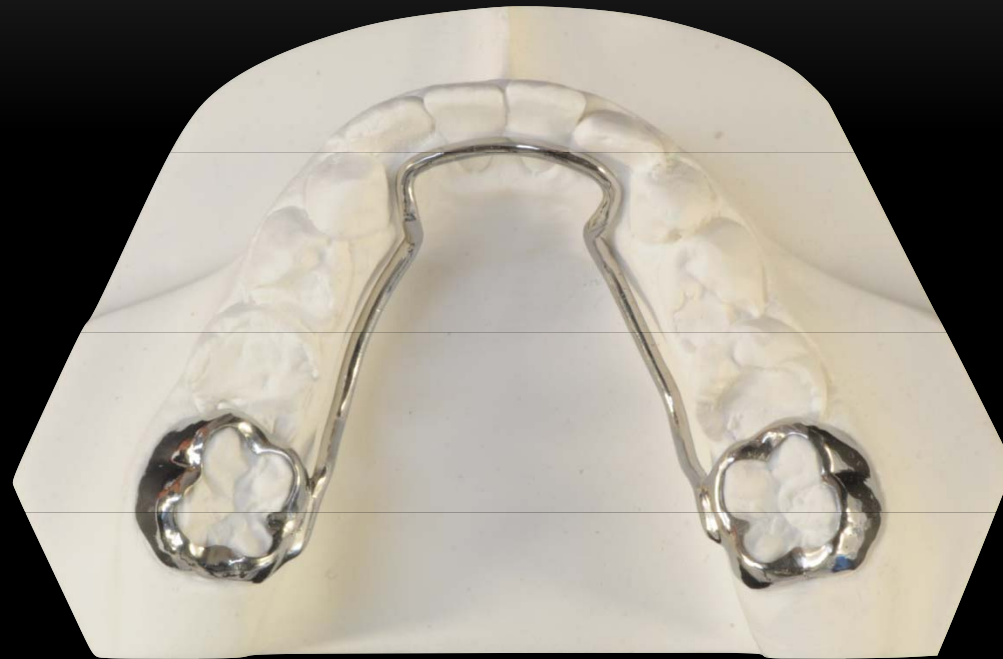





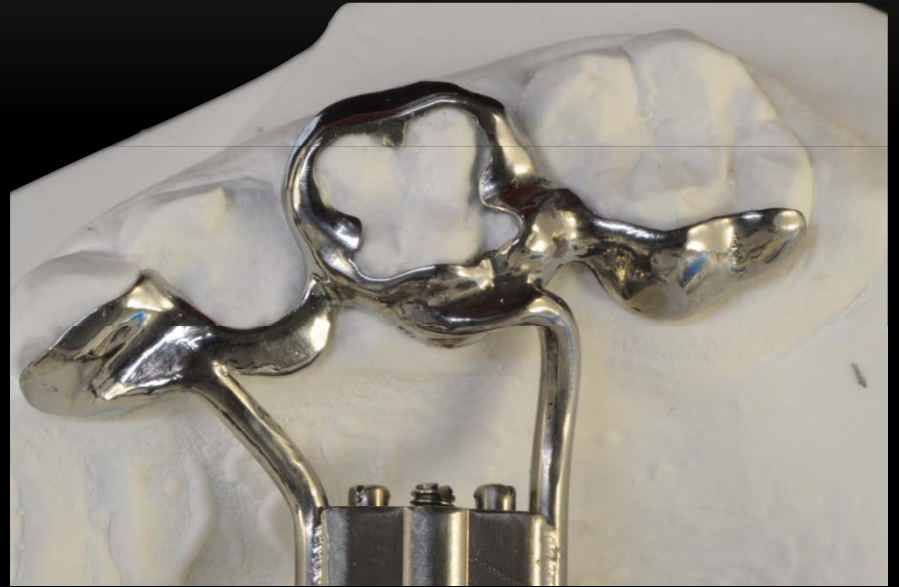
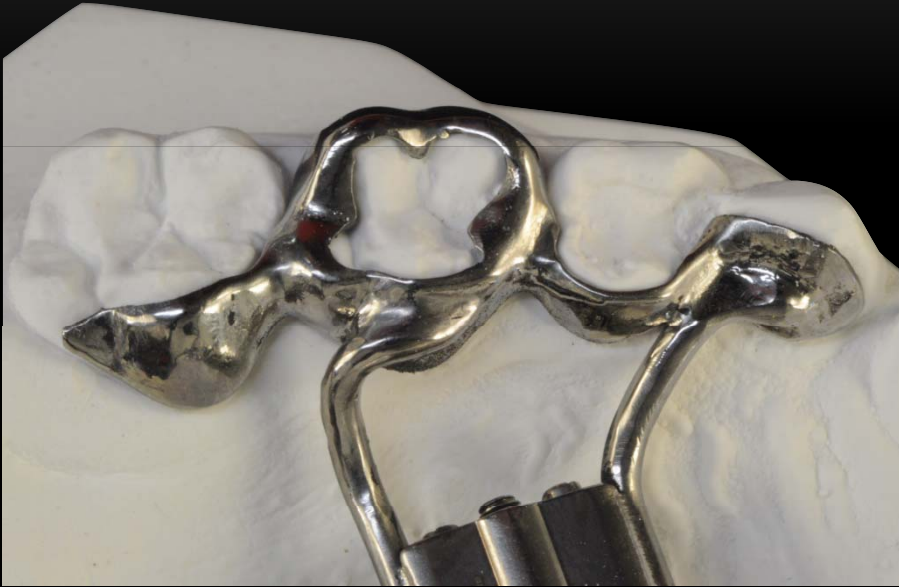




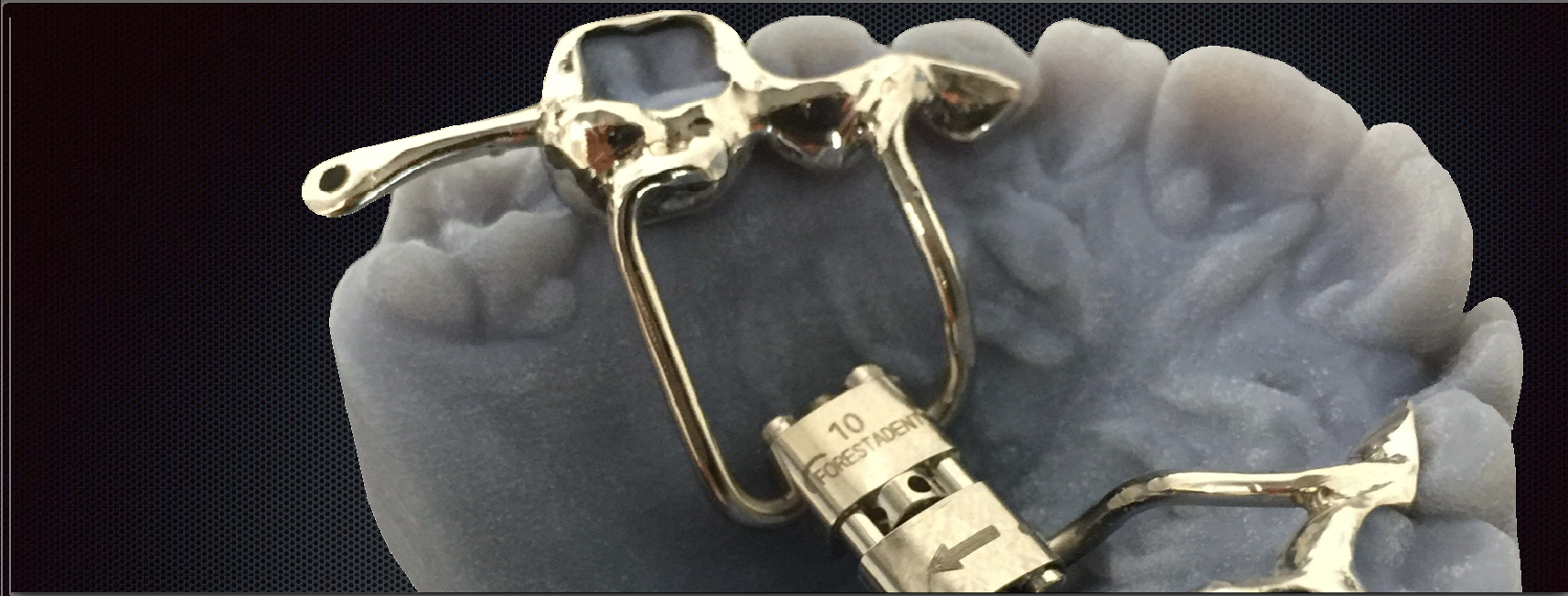





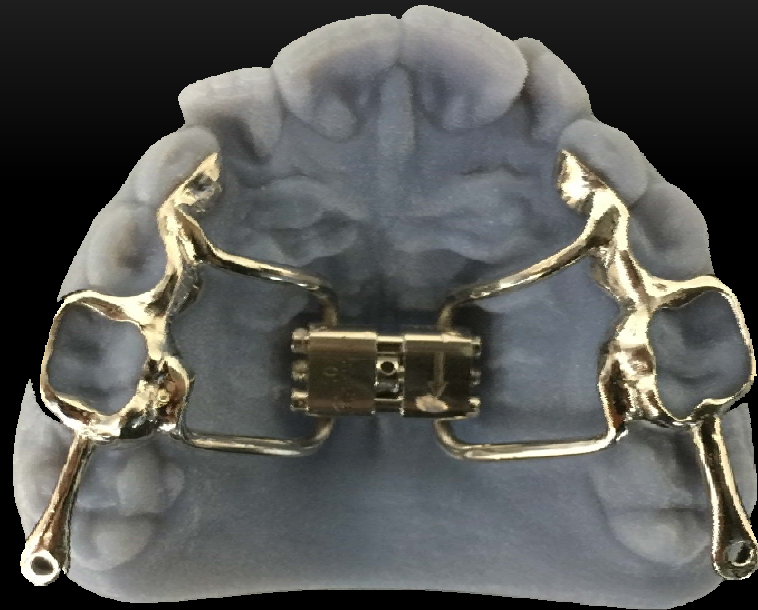



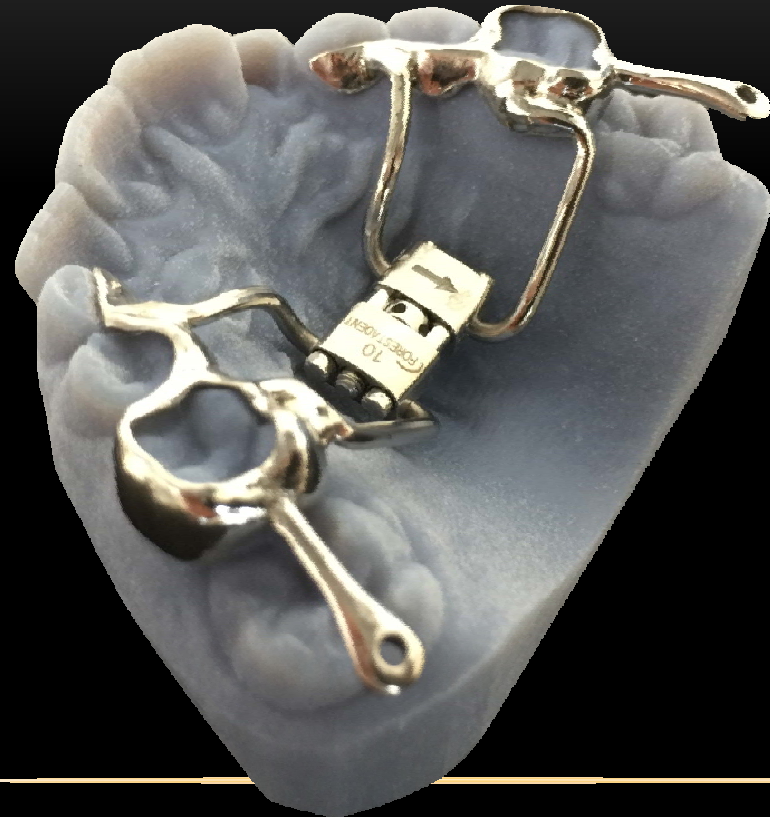


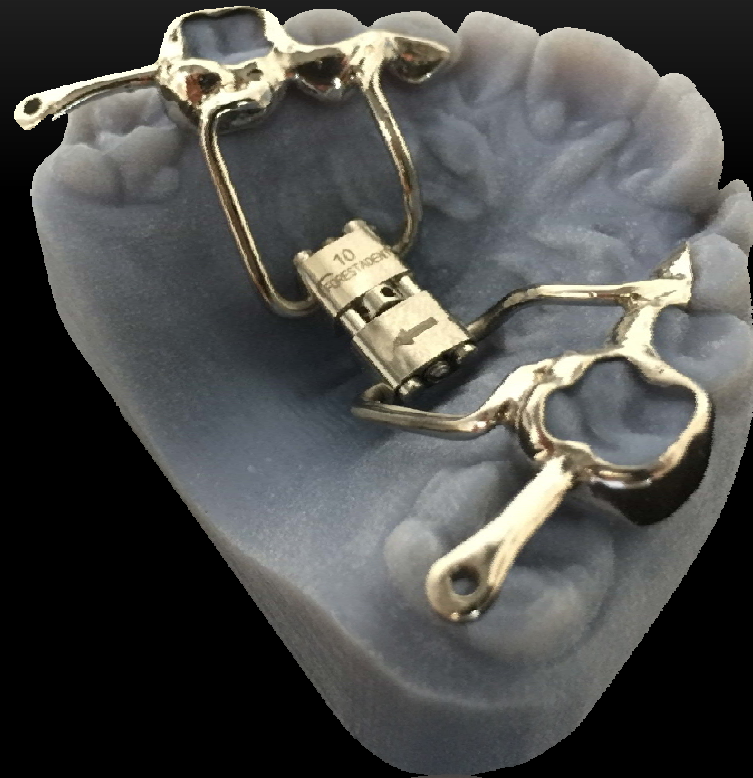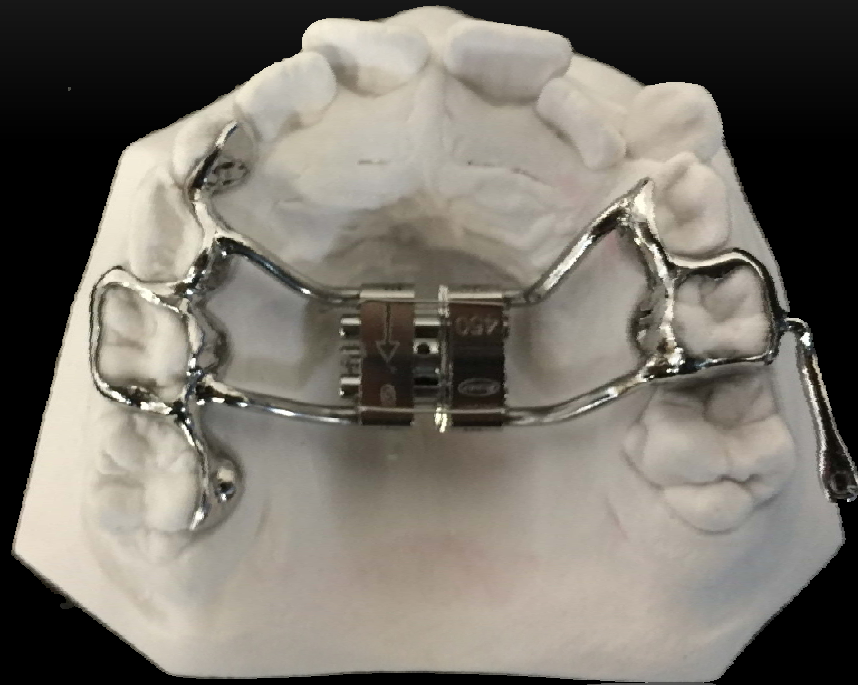# RPE WITH POWER ARMS

---

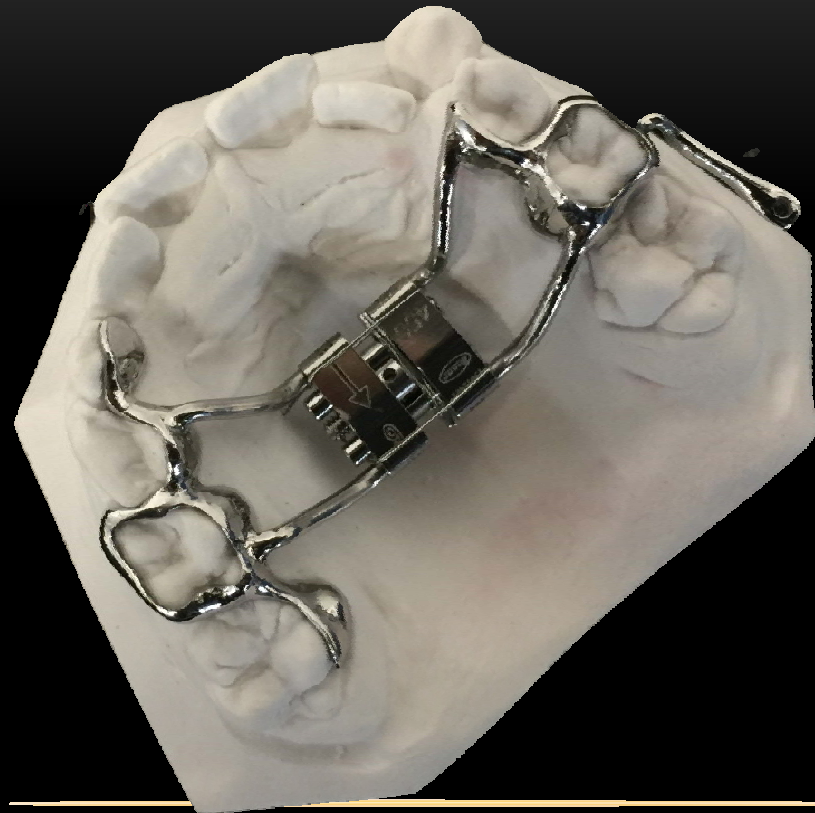




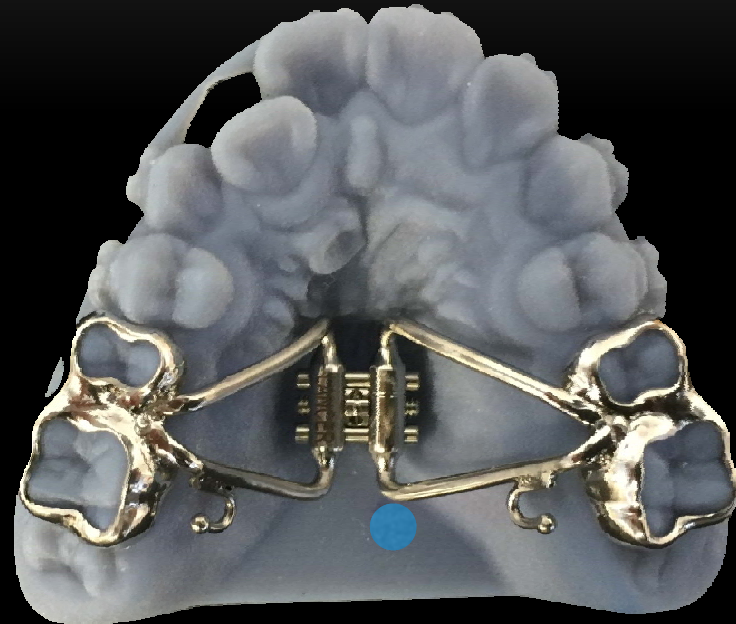


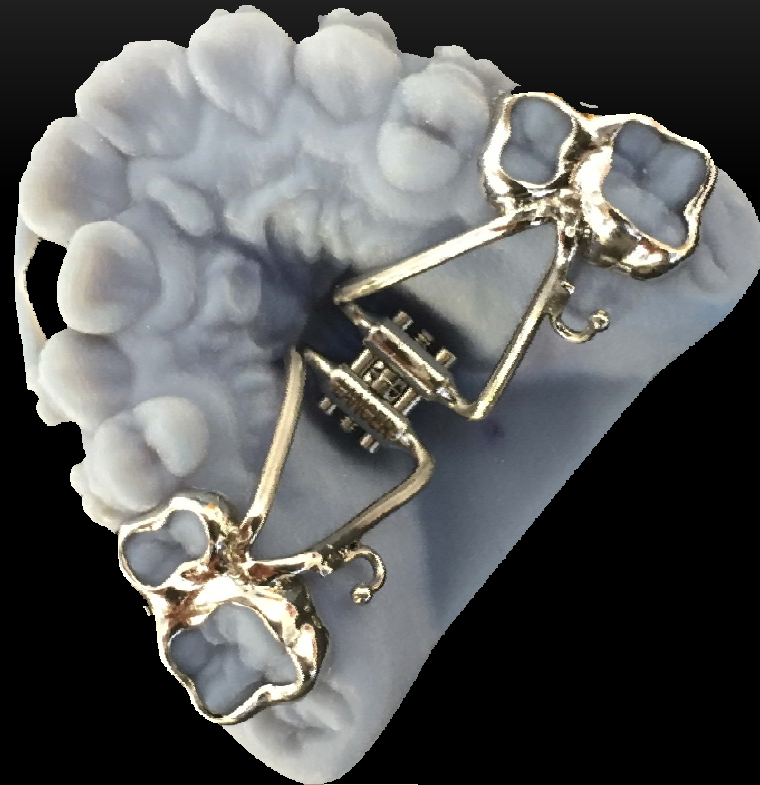


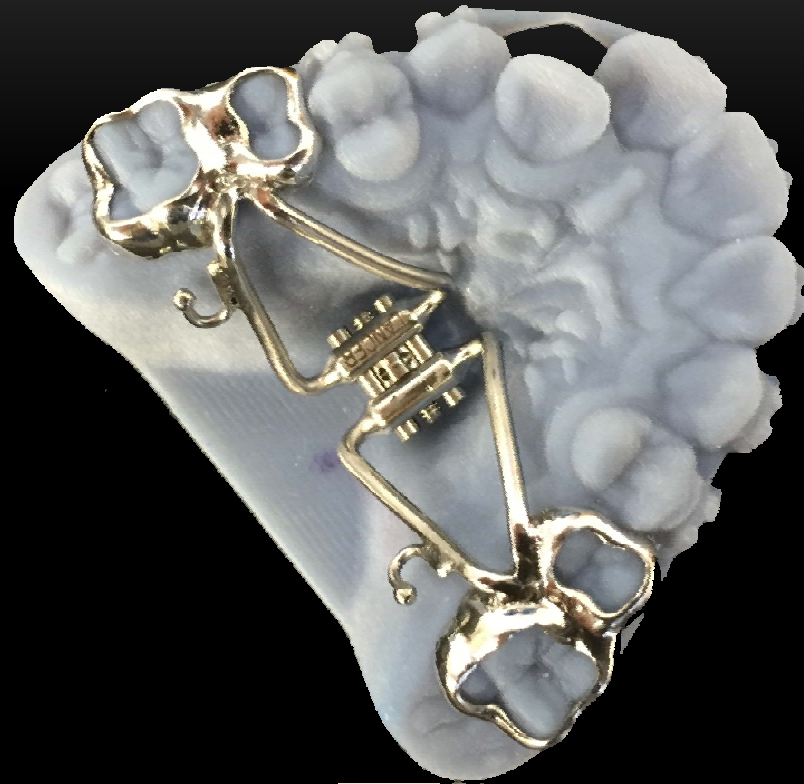
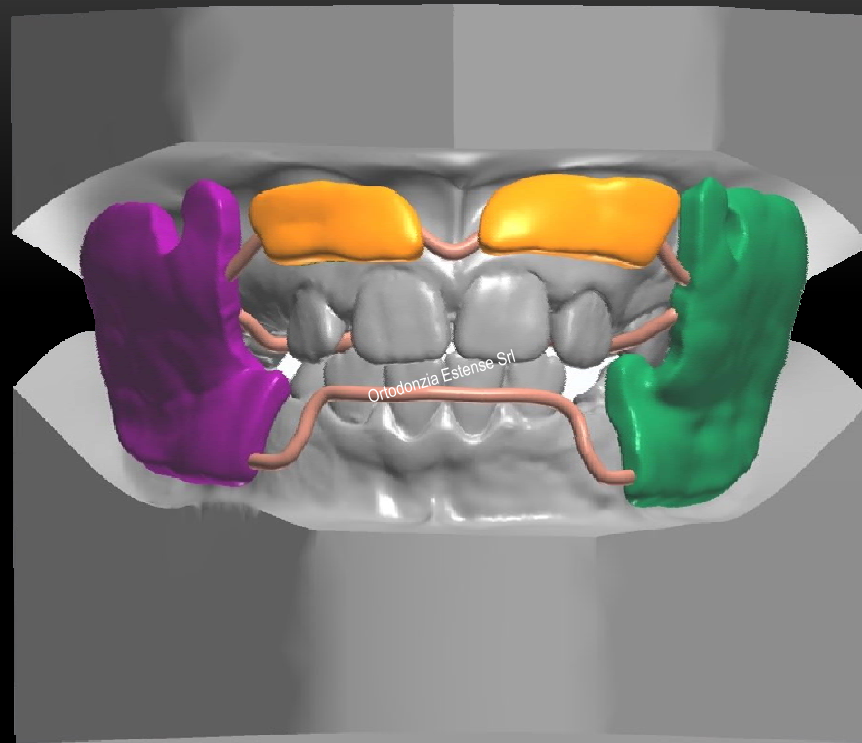






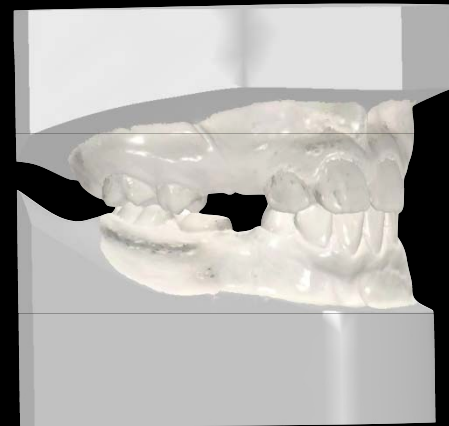
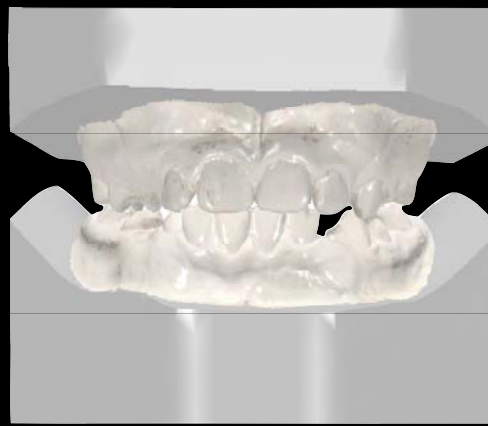
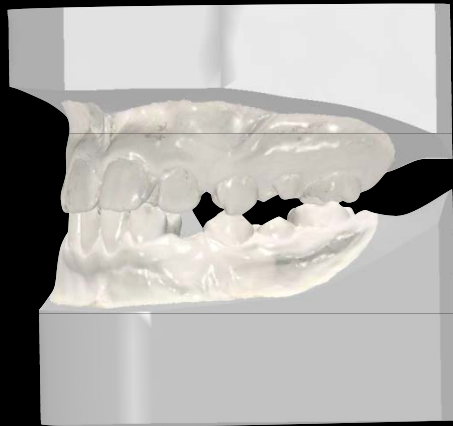
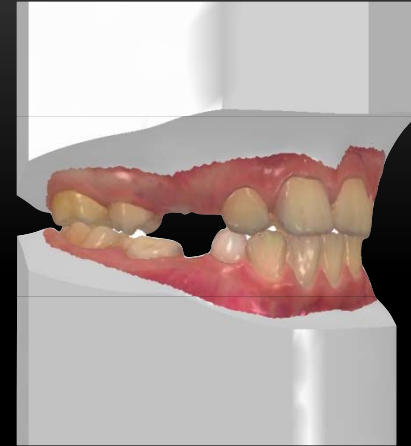
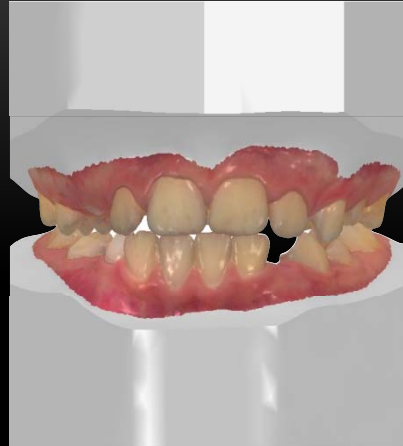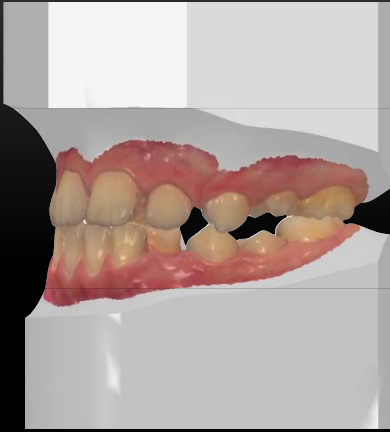


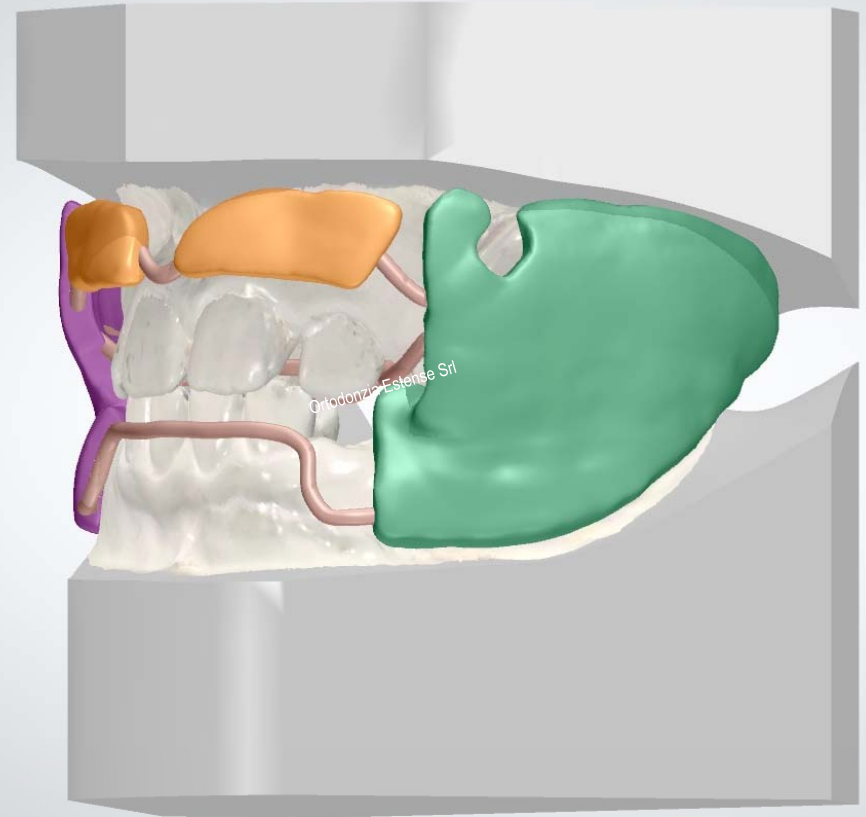




# FRANKEL-3 3D DESIGN

University of Chieti - Sdt. Stefano Negrini

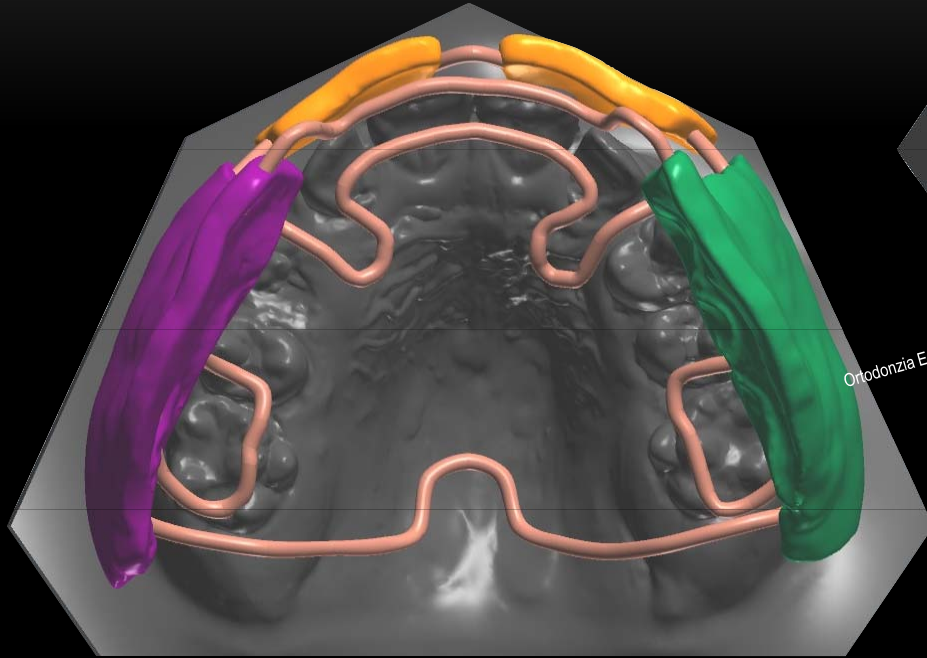




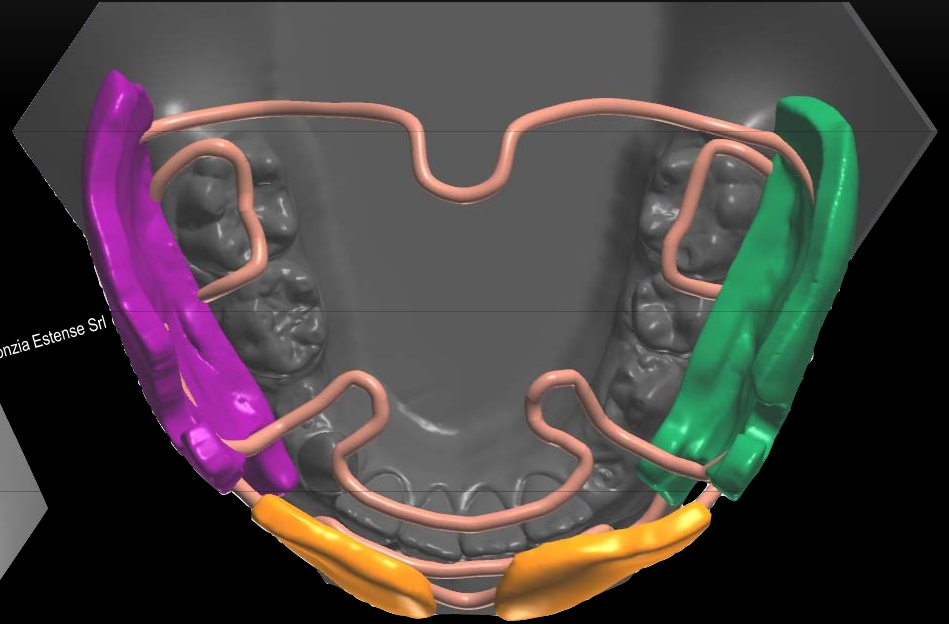
---

We Thank Odt. U. Comparelli  
<http://www.felicefesta.it/team.html>





Ortodonzia Estense Srl



• GRAZIE

